

**Original Article**

## ***Apis mellifera intermissa* venom attenuated colitis-associated cancer progression in azoxymethane treated mice**

**Faouzi Dahdouh<sup>1,2\*</sup>, Hanane Chainez Djeflal<sup>1</sup>, Amira Bourouba<sup>1</sup>, Rania Bousba<sup>1</sup>, Amina Bourouba<sup>1</sup>, Houria Djebbar-Berrebbah<sup>1</sup>**

1. Department of Biology, Laboratory of Cell Toxicology, Faculty of Sciences, Badji-Mokhtar, Annaba University, Annaba, BP 23000, Algeria.

2. Department of Natural Sciences, Higher School of Technological Education, Skikda 21000, Algeria.

**Article Info:**

**Received:** 20 December 2024

**Revised:** 12 January 2025

**Accepted:** 12 January 2025

**Keywords:**

Colitis-associated cancer,  
Azoxymethane,  
Hematological parameters,  
*Apis mellifera intermissa* venom,  
mice.

### **ABSTRACT**

Colitis-associated colorectal cancer (CAC) is a serious condition driven by chronic inflammation in the colon, representing a significant challenge in both preventative and therapeutic contexts. *Apis mellifera intermissa* venom has shown promising therapeutic potential in various disease models, particularly those involving inflammation and tumorigenesis. This study evaluates the therapeutic effects of venom derived from honeybees native to Algeria on the progression of CAC in azoxymethane (AOM)-treated mice. A total of 28 male mice were randomly allocated into four groups (n=7 per group): a control group received a tap drinking water, an AOM group (10 mg AOM /kg body weight), a bee venom group (0.76 mg/kg body weight), and a combined bee venom + AOM group. CAC was induced in mice by a single intraperitoneal injection (i.p) of AOM, and a high-fat diet (45% fat by diet weight) for two weeks. The potential therapeutic effect was evaluated by administering bee venom intraperitoneally on a daily basis for two weeks. AOM significantly reduced body weight, food and water intake while increasing colon weight. Hematological analysis revealed significant reductions in red blood cells (RBC), hemoglobin (HGB), and hematocrit (HCT), coupled with increased white blood cell counts, mean corpuscular volume (MCV), and mean corpuscular hemoglobin (MCH). Elevated serum C-reactive protein (CRP) levels further confirmed systemic inflammation. Macroscopic examination and histopathological analyses of the colon revealed extensive pathological changes in the AOM group, including severe mucosal inflammation, necrotic epithelial damage, and substantial immune cell infiltration. Noteworthy, co-treatment with bee venom effectively mitigated these pathological alterations. Bee venom significantly restored hematological profiles by improving RBC count, HGB, and HCT levels while reducing the elevated WBC count, MCV, and MCH values. CRP levels were significantly reduced, reflecting the anti-inflammatory effects of the venom. Also, macroscopic evaluations demonstrated the preservation of colon morphology, while histopathological assessments revealed an improved epithelial integrity with fewer signs of necrosis and cellular atypia. These findings suggest that *Apis mellifera intermissa* venom holds potential as an adjunct therapeutic agent for suppressing CAC progression, warranting further investigation into its underlying mechanisms and clinical applicability.

**Corresponding Author:**

**f.dahdouh@enset-skikda.dz**



**How to cite this article:** Dahdouh F, Djeflal HC, Bourouba A, Bousba R, Bourouba A, Djebbar – Berrebbah Houria. *Apis mellifera intermissa* venom attenuated colitis-associated cancer progression in azoxymethane treated mice. *Archives of Razi Institute*. 2025;80(3):711-718. DOI: 10.32592/ARI.2025.80.3.711



## 1. Introduction

Colitis-associated cancer (CAC) is a severe complication of chronic inflammatory diseases (CIDs) resulting in increased risk of colorectal cancer (CRC) (1). Although advances in understanding its pathogenesis, CAC remains challenging to treat due to the involvement of chronic inflammation, oxidative stress, and tumorigenesis (2). Conventional therapies often target inflammatory pathways, however, the undesirable side effects limit their effectiveness using novel therapeutic agents with potent anti-inflammatory and anti-cancer properties (3). Moreover, hematological profiles provide essential insights into the systemic inflammation and immune dysregulation in CAC progression in animal models (4).

Bee venom (BV), a natural compound produced by the honeybee *Apis mellifera*, has been extensively studied for its therapeutic potential, with known anti-inflammatory, anti-microbial, and anti-cancer effects (5). While various bee species and subspecies produce venoms with distinct compositions, the venom from *Apis mellifera intermissa*, an Algerian subspecies adapted to the Mediterranean climate, remains understudied (6). Interestingly, BV is rich in biologically active peptides, including melittin, apamin, and phospholipase A2, which have demonstrated promise in modulating immune responses and inducing apoptosis in cancer cells. These bioactive components suggest that *Apis mellifera intermissa* venom could be a valuable candidate for preventing or attenuating CAC progression (7, 8).

This study investigates the potential of *Apis mellifera intermissa* venom collected in Algeria to attenuate CAC progression in mice. Using an azoxymethane (AOM)-induced model of colitis-associated cancer, we evaluate the venom's efficacy in reducing colon tumor incidence and modulating key inflammatory parameter. By exploring this unique venom's potential as an anti-cancer and anti-inflammatory agent, we aim to identify a novel, nature-derived approach for managing CAC, potentially offering new therapeutic insights into the treatment of inflammation-driven cancers.

## 2. Materials and Methods

Twenty-eight Swiss male mice of 3 weeks old provided by Algiers Institute of Algeria were housed in the animal house of our institution maintained by standard laboratory conditions (temperature of 21°C±2, 12h/12h light/dark,

and appx 55% humidity). After two weeks, animals were randomly divided into four main group of seven animal each. A control group (G1) received standard diet and tap drinking water, a Colitis-Associated Cancer (CAC) group (G2) treated with a single intraperitoneally injection of azoxymethane (AOM; Sigma-Aldrich) at a dose of 10 mg/kg body weight, and fed a high-fat diet(45% fat by diet composition) for two weeks, bee venom (BV) group (G3) received an intraperitoneal injection of *Apis mellifera intermissa* venom provided by the Algerian beekeeper start-up company “Nahl Tech” at a dose of 0.76 mg/kg body weight, equivalent to 1/15 of the lethal dose (LD50) as previously determined (9) and a BV treated AOM group (G4). The third and the fourth groups (G3 and G4) were treated daily and over two weeks. Body weight, as well as water and food intake, were monitored every two days during the treatment period to assess the general health and physiological responses of both control and treated groups. At the end of the treatment period, animals were sacrificed by decapitation following anesthesia to minimize pain and stress. Blood samples were collected in two types of tubes: Ethylenediaminetetraacetic acid (EDTA) tubes for hematological analysis and serum separator tubes for measuring C-reactive protein (CRP) levels, an important marker of systemic inflammation. Following blood collection, the colons were carefully removed, rinsed with normal saline to eliminate residual contents, and weighed to assess potential tumor burden or inflammation-related swelling. The colonic tissues were then subjected to both macroscopic examinations to identify visible inflammation, and microscopic examination for detailed histopathological analysis, including the assessment of inflammation, dysplasia, and neoplastic changes. All animal experiments were performed according to the guidelines and regulations set forth by Ministry of Higher Education and Scientific Research of Algeria, in compliance with ethical standards for the care and use of laboratory animals (Approval number PRFU/2022; D01N01EN210120220001).

### 2.1. Determination of hematological and inflammatory parameters

Hematological parameters, including white blood cell (WBC), red blood cell (RBC), hemoglobin (HGB), hematocrit (HCT), mean corpuscular volume (MCV), mean corpuscular hemoglobin (MCH), and mean corpuscular hemoglobin concentration (MCHC) were determined by automated hematology analyzer (Sysmex XP-300, USA). The C-reactive protein (CRP) was

determined by immunoturbidimetry using a commercially available kit.

## 2.2. Macroscopic and microscopic examinations

Macroscopic (or gross) examination involves the visual inspection of the colon morphology based on the appearance of visible inflammations without the use of a microscope. While microscopic examination involves using histological staining techniques (e.g., Hematoxylin and Eosin or H&E) according to the previously described method (10) to observe cellular and tissue-level changes in the colon.

## 2.3. Statistical analysis

The data are given as mean  $\pm$  standard error of the mean (SEM). Groups were compared for the statistical differences by one-way ANOVA, using GraphPad Prism 5.0 (Prism 5 for Windows, version 5) where  $p < 0.05$  was considered significant.

# 3. Results

## 3.1. Physiological changes

The results indicated in Table 1 revealed that azoxymethane (AOM) significantly impacted the studied physiological parameters compared to the control group. Final body weight in the AOM group ( $20.07 \pm 1.33$  g) was markedly reduced compared to the control ( $32.85 \pm 1.09$  g,  $p < 0.01$ ), while the AOM + bee venom (BV) group showed a partial recovery ( $24.13 \pm 1.65$  g,  $p < 0.01$  vs control,  $p < 0.05$  vs AOM). Colon weight was significantly increased in the AOM group ( $0.42 \pm 0.05$  g) compared to the control ( $0.25 \pm 0.01$  g,  $p < 0.001$ ), while AOM + BV reduced this weight ( $0.32 \pm 0.02$  g,  $p < 0.01$  vs control,  $p < 0.01$  vs AOM). Food intake in the AOM group ( $8.28 \pm 1.85$  g) was substantially lower than in the control ( $16.47 \pm 0.92$  g,  $p < 0.001$ ), but improved in the AOM + BV group ( $11.71 \pm 0.60$  g,  $p < 0.01$  vs control,  $p < 0.01$  vs AOM). Similarly, water intake was significantly reduced in the AOM group ( $40.56 \pm 6.43$  mL) compared to the control ( $66.53 \pm 1.78$  mL,  $p < 0.01$ ), while AOM + BV partially restored it ( $54.47 \pm 1.83$  mL,  $p < 0.001$  vs AOM). These findings suggest that BV treatment mitigates some of the detrimental effects of AOM, particularly on body and colon weight, food intake, and water intake, though full recovery to control levels was not achieved.

## 3.2. Changes in hematological profiles

The hematological data reveal notable differences between the control, AOM, BV and AOM + BV groups. White blood cell (WBC) counts significantly increased in the AOM group ( $21.73 \pm 2.25 \times 10^6/\mu\text{L}$ ) compared to the

control ( $13.7 \pm 1.24 \times 10^6/\mu\text{L}$ ,  $p < 0.001$ ), but were moderated in the AOM + BV group ( $15.6 \pm 1.4 \times 10^6/\mu\text{L}$ ,  $p < 0.01$  vs control,  $p < 0.05$  vs AOM). Red blood cell (RBC) counts were substantially reduced in the AOM group ( $5.15 \pm 0.51 \times 10^6/\mu\text{L}$ ) compared to the control ( $9.96 \pm 0.12 \times 10^6/\mu\text{L}$ ,  $p < 0.001$ ), with partial recovery in the AOM + BV group ( $8.02 \pm 0.2 \times 10^6/\mu\text{L}$ ,  $p < 0.05$  vs AOM). Hemoglobin (Hb) levels also dropped significantly in the AOM group ( $7.8 \pm 0.38$  g/dL) versus control ( $15.85 \pm 2.43$  g/dL,  $p < 0.001$ ), with improvement in the AOM + BV group ( $11.7 \pm 0.2$  g/dL,  $p < 0.01$  vs control,  $p < 0.001$  vs AOM). Hematocrit (Hct) levels were reduced in AOM ( $29.4 \pm 2.4\%$ ) compared to control ( $35.2 \pm 0.67\%$ ,  $p < 0.01$ ), with AOM + BV showing partial improvement ( $32.6 \pm 1.3\%$ ,  $p < 0.05$  vs AOM). Mean corpuscular volume (MCV) and mean corpuscular hemoglobin (MCH) were markedly altered, with AOM significantly decreasing MCV ( $33.2 \pm 1.8$  fl) and increasing MCH ( $29.2 \pm 0.1$  pg,  $p < 0.001$  for both vs control). The AOM + BV group mitigated these changes (MCV:  $39.7 \pm 2.2$  fl,  $p < 0.01$  vs control; MCH:  $25.2 \pm 0.1$  pg,  $p < 0.01$  vs control).

These findings suggest that BV ameliorates the hematological damage caused by AOM, although complete normalization is not observed (Table 2).

## 3.3. Macroscopic observations of colon

Figure 1 illustrates the macroscopic effects of colitis in mice subjected to different treatments, highlighting the protective role of bee venom (BV). In azoxymethane (AOM)-treated mice (panel b), the colon exhibits severe inflammatory colitis characterized by prominent colonic ulceration (denoted by \*), thickened colon walls (arrows), and a reddish discoloration, indicating substantial inflammation and tissue damage. In contrast, the AOM+BV-treated mice (panel d) show a marked reduction in these pathological features, with significantly less inflammation, thinner colon walls, and the absence of prominent ulceration, suggesting that BV mitigates the severity of colitis. Notably, mice treated solely with BV (panel c) display no significant morphological changes, indicating that BV does not induce colonic alterations or inflammation in the absence of AOM. This visual comparison underscores the therapeutic potential of BV in alleviating colitis induced by AOM.

## 3.4. Microscopic observations of colon

As shown in Figure 2, colon tissue from control mice (Figure 2a) revealed normal and intact colon histological

**Table 1.** Body weight changes, food and water intake and colon weight changes in control group, AOM, BV and AOM + BV groups.

	Control	AOM	BV	AOM+BV
<b>Initial body weight (g)</b>	26.61±0.85	27.58±0.87	26.48±1.55	27.39±0.87
<b>Final body weight (g)</b>	32.85±1.09	20.07±1.33**	29.95±1.21	24.13±1.65** <sup>a</sup>
<b>Colon weight (g)</b>	0.25± 0.01	0.42±0.05**	0.24 ±0.03	0.32 ± 0.02** <sup>b</sup>
<b>Food intake (g)</b>	16.47±0.92	8.28 ± 1.85***	14.81±1.57	11.71±0.60** <sup>b</sup>
<b>Water intake (mL)</b>	66.53±1.78	40.56 ± 6.43**	64.95±5.58	54.47±1.83* <sup>c</sup>

Data are given in mean ± standard error of the mean (SEM).

\* $p<0.05$ , \*\* $p<0.01$  and \*\*\* $p<0.001$  are statistically different from control.

<sup>a</sup> $p<0.05$ , <sup>b</sup> $p<0.01$  and <sup>c</sup> $p<0.001$  are statistically different from AOM.

AOM: Azoxymethane (10mg/kg body weight, i.p once for 2 weeks).

BV: Bee venom (0.76 5mg/kg body weight, i.p for two weeks).

**Table 2.** Changes in hematological profiles, white blood cell (WBC), red blood cell (RBC), hemoglobin (HGB), hematocrit (HCT), mean corpuscular volume (MCV), mean corpuscular hemoglobin (MCH), and mean corpuscular hemoglobin concentration (MCHC) in control group, AOM, BV and AOM + BV groups.

	Control	AOM	BV	AOM+BV
<b>WBCs (10<sup>6</sup>/μl)</b>	13.7 ± 1.24	21.73 ± 2.25***	13.05 ± 0.81	15.6 ± 1.4** <sup>a</sup>
<b>RBC (10<sup>6</sup>/μl)</b>	9.96 ± 0.12	5.15 ± 0.51***	8.88 ± 0.18	8.02 ± 0.2* <sup>b</sup>
<b>Hb (g/dl)</b>	15.85 ± 2.43	7.8 ± 0.38***	14.7 ± 1.03	11.7 ± 0.2** <sup>c</sup>
<b>Hct (%)</b>	35.2 ± 0.67	29.4 ± 2.4**	34.8 ± 1.38	32.6 ± 1.3* <sup>a</sup>
<b>MCV (fl)</b>	44.2 ± 0.67	33.2 ± 1.8**	43.2 ± 1.03	39.7 ± 2.2** <sup>a</sup>
<b>MCH (pg)</b>	22.8 ± 0.17	29.2 ± 0.1***	21.43 ± 0.09	25.2 ± 0.1** <sup>a</sup>
<b>MCHC (g/dl)</b>	377 ± 5.8	522 ± 7.3***	374 ± 4.61	420 ± 6.7** <sup>b</sup>

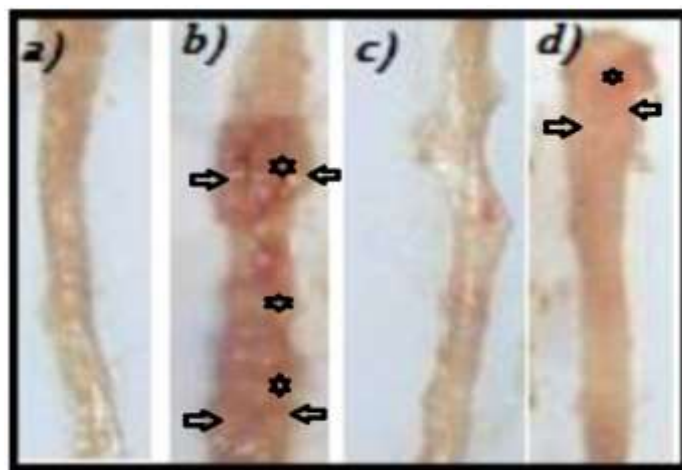
Data are given in mean ± standard error of the mean (SEM).

\* $p<0.05$ , \*\* $p<0.01$  and \*\*\* $p<0.001$  are statistically different from control.

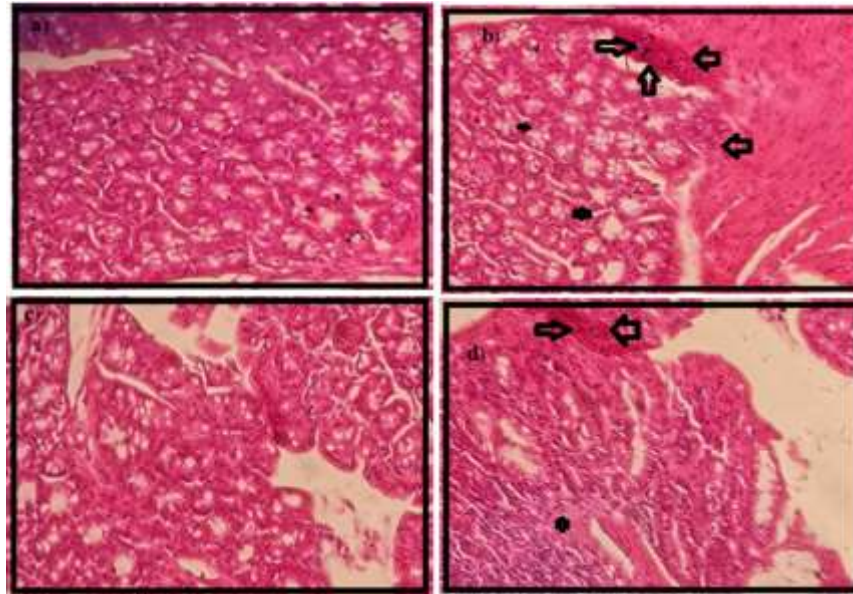
<sup>a</sup> $p<0.05$ , <sup>b</sup> $p<0.01$  and <sup>c</sup> $p<0.001$  are statistically different from AOM.

AOM: Azoxymethane (10mg/kg body weight, i.p once for 2 weeks).

BV: Bee venom (0.76 5mg/kg body weight, i.p for two weeks).

**Figure 1.** Macroscopic view of colon morphology in control and treated groups; control mice (a) showing normal a normal, and healthy structure, (b) azoxymethane-treated mice showing sever inflammatory colitis associated with colonic ulceration (\*), thickened colon walls (arrows), and reddish color of colon. These signs are significantly reduced in AOM+BV (d). While BV treatment shows no marked morphological changes in colon (c).





**Figure 2:** Microscopic view (Leica Microsystems, Germany) of colon histology from control and treated mice; Colon tissue from control mice (a) showing normal histological architecture, and azoxymethane (AOM)-treated mice (b) showing necrotic epithelial damage (\*), and inflammation with immune cell infiltration (arrows), bee venom (BV) treated mice (c) showing no marked histological changes, and AOM+BV mice (d), showing less inflammation and epithelial necrosis. G x 40.

structure evidenced by epithelial glands and tubular cells morphology with cytoplasm and a small basal nucleus. However, colon tissue from azoxymethane (AOM) treated mice showed epithelial damage by necrosis, and inflammation with immune cell infiltration (Fig. 2b). Bee venom treatment did not cause marked changes in the colon histology (Figure 2c). Consequently, bee venom supplementation in AOM-treated mice (Figure 2d) markedly reduced inflammation and immune cell infiltration, and protected against epithelial damage, and hence, lesser colon histological alterations were noticed compared with those found in AOM-treated mice.

#### 4. Discussion

In this study, body weight, food and water intake were significantly decreased in azoxymethane treated mice compared with control. Similarly, some previous studies (11, 12) have reported physiological alterations in AOM treated mice. Azoxymethane (AOM) induces colitis and associated physiological changes in mice through its metabolism into active intermediates, such as methylazoxymethanol, in the liver. This process damages the colonic mucosa, triggering inflammation and tissue remodeling, which explains the observed increase in colon weight due to edema, immune cell infiltration, and hyperplasia (13).

The decrease in body weight following AOM administration is linked to systemic toxicity and inflammation-induced metabolic disturbances, associated with reduced nutrient absorption (14-16). These combined effects mimic the physiological and pathological conditions observed in colitis and colorectal cancer, making AOM a valuable model for studying these diseases. Further, the results of table 1 indicated a marked increase in colon weight in AOM treatment, alike to some previously reported studies (17) suggesting the reason AOM may induce inflammatory and proliferative responses triggered leading to cellular damage. On the other hand, bee venom supplemented AOM treated mice mitigated all the adverse effects of AOM on the above-mentioned physiological indices.

As reported (7), bee venom, known for its anti-inflammatory and antioxidant properties, appears to counteract these effects. BV's active components, such as phospholipase A2 and melittin, help reduce the inflammatory cytokine production and oxidative stress that contribute to tissue damage and impaired gastrointestinal function. Furthermore, our data revealed hematotoxicity associated with AOM exposure, and this was similarly reported in some previous studies (17, 18). The elevated white blood cell (WBC) counts, particularly neutrophils, reflect the chronic inflammatory response

driven by colitis and subsequent tumorigenesis (4). Red blood cell (RBC) counts and hemoglobin (Hb) levels are typically reduced, reflecting anemia due to chronic inflammation and potential gastrointestinal blood loss from ulcerated colon tissues (19).

Additionally, elevated levels of pro-inflammatory cytokines, such as TNF- $\alpha$  and IL-6, in the blood further illustrate the systemic impact of CAC, contributing to a tumor-promoting microenvironment (20). Together, these hematological changes provide a comprehensive picture of the inflammatory and immune responses involved in CAC and are valuable for monitoring disease progression and therapeutic effects. However, bee venom has markedly restored AOM induced colitis in association with hematotoxicity in mice. The protective effect of bee venom and its main components in cancer animal models have been well documented (21). In this regard, BV and its main components owed to their antioxidant properties can neutralize reactive oxygen species (ROS), protecting hematopoietic stem cells from oxidative damage and preventing alterations in blood cell counts (22). Moreover, BV has been shown to improve blood circulation, which may help enhance oxygen delivery to tissues, further promoting normal hematological function (23).

Accordingly, AOM revealed significant colon morphological changes characterized by appearance of inflammatory colitis associated with colonic ulceration, in addition to histological alterations revealed by necrosis in epithelial tissues, and inflammatory reactions with immune cell infiltration. The morphological and histological alterations in AOM induced colitis in animal models are somehow related to induction of oxidative tissue injury and damage, in addition to tissue inflammation (24, 25).

Whilst, these tissue alterations were significantly reduced in bee venom treated mice received AOM. Its beneficial effect are primarily attributed to the presence of bioactive compounds such as melittin, phospholipase A2, and apamin, exhibiting potent anti-inflammatory, antioxidant, and immunomodulatory properties (7).

Conclusively, bee venom is believed to be a substantial therapeutic potential by mitigating inflammation, reducing oxidative stress, and promoting tissue repair. AOM is a potent cancerogenic agent able to induce significant colitis in mice, as evidenced by marked alterations in the physiological, inflammatory and haematological parameters, colon morphology and histology. However,

bee venom treatment successfully mitigated these adverse effects, demonstrating its ability to reduce inflammation, improve haematological parameters, and restore colonic tissue integrity. These findings underscore the therapeutic potential of bee venom as a complementary treatment for inflammation-driven colonic disorders, warranting further investigation into its mechanisms and applications in clinical settings.

### Acknowledgment

The authors thank gratefully the Start-up bee keeper “Nahl Tech” Company of Algeria for providing the venom, and the laboratory technicians of cell toxicology of the valuable assistance.

### Authors' Contribution

Study design, data analysis and writing of the paper: F.D.

Experimental study: HC.D.

Data analysis: A.B, A.B.

Animal handling and treatments: R. B.

Contribution in study design, and providing the lab spaces for experiments: H. BD.

### Ethics

We hereby declare all ethical standards have been respected in preparation of the submitted article.

### Conflict of Interest

None

### Funding

None

### Data Availability

None

### References

1. Grivennikov SI, editor Inflammation and colorectal cancer: colitis-associated neoplasia. *Seminars in immunopathology*; 2013: Springer.
2. Roessner A, Kuester D, Malfertheiner P, Schneider-Stock R. Oxidative stress in ulcerative

colitis-associated carcinogenesis. *Pathology-Research and practice*. 2008;204(7):511-24.

3. Piechota-Polanczyk A, Fichna J. The role of oxidative stress in pathogenesis and treatment of inflammatory bowel diseases. *Naunyn-Schmiedeberg's archives of pharmacology*. 2014;387(7):605-20.

4. Greten FR, Eckmann L, Greten TF, Park JM, Li Z-W, Egan LJ, et al. IKK $\beta$  links inflammation and tumorigenesis in a mouse model of colitis-associated cancer. *Cell*. 2004;118(3):285-96.

5. Ullah A, Aldakheel FM, Anjum SI, Raza G, Khan SA, Gajger IT. Pharmacological properties and therapeutic potential of honey bee venom. *Saudi Pharmaceutical Journal*. 2023;31(1):96-109.

6. Haddad NJ, Loucif-Ayad W, Adjlane N, Saini D, Manchiganti R, Krishnamurthy V, et al. Draft genome sequence of the Algerian bee *Apis mellifera intermissa*. *Genomics data*. 2015;4:24-5.

7. Mirzavi F, Saghi H, Ebrahimi S, Mahdinezhad MR, Hosseini H, Soukhtanloo M. The anti-tumor, anti-oxidative, and anti-inflammatory effects of bee venom in C26 colon carcinoma-bearing mice model. *Iranian Journal of Science*. 2024;48(1):69-75.

8. Aliyazicioglu R. Therapeutic effects of bee venom. *Chem Sci Int J*. 2019;26(1):1-5.

9. Dahdouh F, Belhamzaoui K, Aouadi L, Aldahmash W, Harrath AH, Plavan G, et al. Bee venom causes oxidative stress, biochemical and histopathological changes in the kidney of mice. *Physiological Research*. 2023;72(4):455.

10. Drury R, Wallington E. Carleton's histological technique 5th ed. New York: Churchill Livingstone. 1980:270.

11. Kubota M, Shimizu M, Sakai H, Yasuda Y, Terakura D, Baba A, et al. Preventive effects of curcumin on the development of azoxymethane-induced colonic preneoplastic lesions in male C57BL/KsJ-db/db obese mice. *Nutrition and cancer*. 2012;64(1):72-9.

12. Tak K-H, Ahn E, Kim E. Increase in dietary protein content exacerbates colonic inflammation and tumorigenesis in azoxymethane-induced mouse colon carcinogenesis. *Nutrition Research and Practice*. 2017;11(4):281-9.

13. Tanaka T. Development of an inflammation-associated colorectal cancer model and its application for research on carcinogenesis and chemoprevention. *International journal of inflammation*. 2012;2012(1):658786.

14. Tanaka T. Preclinical cancer chemoprevention studies using animal model of inflammation-associated colorectal carcinogenesis. *Cancers*. 2012;4(3):673-700.

15. Hwang S, Jo M, Hong JE, Park CO, Lee CG, Rhee K-J. Protective effects of zerumbone on colonic tumorigenesis in enterotoxigenic *Bacteroides fragilis* (ETBF)-colonized AOM/DSS BALB/c mice. *International journal of molecular sciences*. 2020;21(3):857.

16. Kangawa Y, Yoshida T, Maruyama K, Okamoto M, Kihara T, Nakamura M, et al. Cilostazol and enzymatically modified isoquercitrin attenuate experimental colitis and colon cancer in mice by inhibiting cell proliferation and inflammation. *Food and Chemical Toxicology*. 2017;100:103-14.

17. Abbas H, Abass D. Amlodipine (P-glycoprotein) inhibitor modulation effect on Doxorubicin's Hematological, Oxidative and Inflammatory effects in Colorectal cancer induced in Mice. *Journal of Survey in Fisheries Sciences*. 2023;10:823-33.

18. Shimpo K, Beppu H, Chihara T, Kaneko T, Shinzato M, Sonoda S. Effects of *Aloe arborescens* ingestion on azoxymethane-induced intestinal carcinogenesis and hematological and biochemical parameters of male F344 rats. *Asian Pacific Journal of Cancer Prevention*. 2006;7(4):585.

19. Langley R, Burdett S, Tierney J, Cafferty F, Parmar M, Venning G. Aspirin and cancer: has aspirin been overlooked as an adjuvant therapy? *British journal of cancer*. 2011;105(8):1107-13.

20. Terzić J, Grivennikov S, Karin E, Karin M. Inflammation and colon cancer. *Gastroenterology*. 2010;138(6):2101-14. e5.

21. Gajski G, Leonova E, Sjakste N. Bee venom: composition and anticancer properties. *Toxins*. 2024;16(3):117.

22. Son DJ, Lee JW, Lee YH, Song HS, Lee CK, Hong JT. Therapeutic application of anti-arthritis, pain-releasing, and anti-cancer effects of bee venom

and its constituent compounds. *Pharmacology & therapeutics*. 2007;115(2):246-70.

23. Kim S-D, Kim J-H, Kim D-H, Park J-H, Gong Y, Sun C, et al. Comprehensive evaluation of traditional herbal medicine combined with adjuvant chemotherapy on post-surgical gastric cancer: a systematic review and meta-analysis. *Integrative Cancer Therapies*. 2024;23:15347354231226256.

24. Zhang H, Wang M, Zhou Y, Bao S, Wang F, Li C. Protective Effects of Astaxanthin against Oxidative Stress: Attenuation of TNF- $\alpha$ -Induced Oxidative Damage in SW480 Cells and Azoxymethane/Dextran Sulfate Sodium-Induced Colitis-Associated Cancer in C57BL/6 Mice. *Marine Drugs*. 2024;22(10):469.

25. Farombi EO, Ajayi BO, Ajeigbe OF, Maruf OR, Anyebe DA, Opafunso IT, et al. Mechanistic exploration of 6-shogaol's preventive effects on azoxymethane and dextran sulfate sodium-induced colorectal cancer: involvement of cell proliferation, apoptosis, carcinoembryonic antigen, wntless-related integration site signaling, and oxido-inflammation. *Toxicology Mechanisms and Methods*. 2025;35(1):1-10.