

Therapeutic Effects of Hydroalcoholic Extract of Black Seed (*Nigella sativa* L.) and Honey on Biochemical Parameters, Thyroid Hormones, and Liver Tissue in Streptozotocin-Induced Diabetic Male Rats

Zainab Rezaei¹, Mokhtar Mokhtari^{2*} and Mehrdad Shariati²

¹ Department of Biology, Islamic Azad University, Kazerun Branch, Kazerun, Iran

² Faculty of Basic Sciences, Department of Biology, Islamic Azad University, Kazerun Branch, Kazerun, Iran

Article Info

Article Type

Original Article

Article History

Received: 03 October 2024

Accepted: 13 December 2024

© 2012 Iranian Society of Medicinal Plants.

All rights reserved.

*Corresponding author

m.mokhtari246@yahoo.com



ABSTRACT

This study aimed to evaluate the therapeutic effects of hydroalcoholic extract of black seed (*Nigella sativa* L.) and honey on biochemical parameters, thyroid hormones, and liver tissue in streptozotocin-induced diabetic adult male rats. Seventy male Wistar rats were divided into seven groups: control, placebo, diabetic control, and experimental groups receiving 2 g/kg and 4 g/kg of the extract and honey for 21 days. Serum levels of thyroid hormones, cholesterol, triglycerides, LDL, HDL, albumin, and total protein were measured. Liver histology was assessed to determine the extent of tissue damage. The results demonstrated that treatment with 2 g/kg and 4 g/kg of black seed and honey significantly improved lipid profiles, increased HDL, and reduced triglycerides and LDL levels ($p < 0.05$). Thyroid hormone regulation improved, with increased T3 and stabilized TSH levels. Histological analysis revealed reduced liver necrosis and inflammation in the treated groups, highlighting the hepatoprotective effects of the extract. Overall, the combination of *N. sativa* and honey significantly mitigated the adverse effects of diabetes, offering a promising natural treatment strategy for managing diabetes and its complications.

Keywords: *Nigella sativa*, Honey, Diabetes, Thyroid hormones, Liver tissue

How to cite this paper

Rezaei, Z., Mokhtari, M., Shariati, M. Therapeutic Effects of Hydroalcoholic Extract of Black Seed (*Nigella sativa* L.) and Honey on Biochemical Parameters, Thyroid Hormones, and Liver Tissue in Streptozotocin-Induced Diabetic Male Rats. Journal of Medicinal Plants and By-products, 2025; 14(4):374-380. doi: 10.22034/jmpb.2024.367237.1777

INTRODUCTION

Diabetes mellitus is a chronic metabolic disorder characterized by elevated blood glucose levels, resulting from insufficient insulin production or impaired insulin action. It has become a global health crisis, affecting over 537 million adults worldwide as of 2021, with projections reaching 783 million by 2045 [1]. The disease is associated with severe complications, including cardiovascular diseases, kidney failure, neuropathy, retinopathy, and an increased risk of mortality [2-4]. Managing diabetes requires long-term lifestyle changes and pharmacological interventions, posing significant economic and social burdens on healthcare systems [5]. The increasing prevalence of type 2 diabetes, driven by factors such as sedentary lifestyles, obesity, and unhealthy diets, heightens concerns about the global healthcare infrastructure's ability to address this growing epidemic [6]. Moreover, diabetes-related complications significantly reduce the quality of life and highlight the urgent need for innovative therapeutic strategies and effective public health measures. Diabetes mellitus profoundly disrupts various biochemical parameters, significantly impacting glucose and lipid homeostasis. The primary feature of hyperglycemia leads to elevated fasting blood glucose levels due to compromised insulin secretion or action, which is often accompanied by dyslipidemia characterized by increased triglycerides and low-density lipoprotein (LDL), along with decreased high-density lipoprotein (HDL) [7], raising cardiovascular risk [8]. Additionally, oxidative stress is exacerbated, marked by elevated reactive oxygen species (ROS)

and malondialdehyde (MDA) [9], contributing to tissue damage through an imbalance in antioxidant defenses. Diabetes also affects the endocrine system, particularly thyroid hormone regulation, with altered hypothalamic-pituitary-thyroid (HPT) axis activity leading to subclinical hypothyroidism, further impairs glucose metabolism [10, 11]. Moreover, the liver is susceptible to damage from diabetes, promoting conditions like non-alcoholic fatty liver disease (NAFLD) and non-alcoholic steatohepatitis (NASH) [12]. The oxidative stress and inflammation associated with diabetes contribute to liver injury, underscoring the need for careful monitoring and management to prevent severe complications, such as cirrhosis or hepatocellular carcinoma. Medicinal plants as a natural and safer alternative for treating diseases, particularly in conditions like diabetes, have gained increasing attention [13]. Medicinal plants possess bioactive compounds such as flavonoids, alkaloids, phenols, and terpenes, which can regulate metabolic processes and reduce inflammatory factors and oxidative stress—key contributors to cellular damage in diseases like diabetes [14]. In contrast to synthetic drugs, which may have significant side effects such as hepatic or renal toxicity, medicinal plants are generally associated with fewer adverse effects and, in some cases, provide multiple therapeutic benefits. Moreover, utilizing these natural resources aligns with traditional and indigenous medicine approaches, promoting sustainable and environmentally friendly practices that allow for the production of cost-effective and accessible treatments. Given the rising concerns about drug resistance and the negative impacts of synthetic

medications, the shift towards medicinal plants as a safer and more holistic therapeutic strategy, especially for chronic diseases like diabetes, has become increasingly significant. The hydroalcoholic extract of black seed (*Nigella sativa*) has garnered considerable attention for its potential antidiabetic properties, attributed primarily to its bioactive compounds, including thymoquinone, alkaloids, and flavonoids [15, 16]. Research has demonstrated that these constituents can enhance insulin sensitivity, lower blood glucose levels, and improve overall metabolic function. Heshmati *et al.* (2015) indicated that treatment with black seed extract significantly reduced fasting blood glucose levels and improved lipid profiles in diabetic rats [17]. Additionally, the antioxidant properties of *N. sativa* may help mitigate oxidative stress, which plays a critical role in the pathogenesis of diabetes and its complications [18]. By reducing oxidative damage, black seed extract could contribute to better glycemic control and lower the risk of diabetes-related complications. The combination of hydroalcoholic extract of black seed with honey has also been investigated for its synergistic effects on diabetes management [19]. Honey, known for its natural sweetness and therapeutic properties, has been shown to possess anti-inflammatory, antioxidant, and wound-healing effects. A study by Mohamad *et al.* (2014) reported that the co-administration of black seed extract and honey in diabetic animals resulted in a more pronounced reduction in blood glucose levels compared to either treatment alone [20]. This combination not only enhances the therapeutic efficacy of black seed but also helps in improving overall metabolic health. Furthermore, the natural sugars present in honey may provide a balanced source of energy without causing significant spikes in blood glucose levels, making it a suitable adjunct in diabetic diets. Moreover, the therapeutic effects of hydroalcoholic extracts of black seed and honey extend beyond glycemic control to include improvements in liver function and lipid metabolism. Research by Abdallah *et al.* (2016) highlighted that both black seed and honey exhibited hepatoprotective effects in diabetic rats, evidenced by decreased levels of liver enzymes such as alanine aminotransferase (ALT) and aspartate aminotransferase (AST) [21]. The anti-inflammatory properties of these substances may also play a vital role in reducing liver inflammation associated with diabetes [22]. Thus, the incorporation of hydroalcoholic extract of black seed and its combination with honey represents a promising strategy for managing diabetes and its complications, with potential benefits supported by various studies. This study aims to investigate the therapeutic effects of hydroalcoholic extract of black seed and its combination with honey on biochemical parameters, thyroid hormones, and liver tissue in streptozotocin-induced diabetic male rats. By focusing on these specific outcomes, the research seeks to elucidate the mechanisms through which these natural compounds exert their beneficial effects, thereby contributing to the development of effective and safe alternative treatments for diabetes. Ultimately, the findings could pave the way for integrating herbal remedies into conventional diabetes management, promoting a more comprehensive approach to tackling this chronic disease and its associated complications.

MATERIALS AND METHODS

Animal Subjects

In this experimental study, 70 adult male Wistar rats, weighing approximately 200 to 220 grams and aged between 2.5 to 3 months, were utilized. The rats were housed in specially designed cages with standard space, under suitable environmental

conditions, at a temperature of 20-24°C, with a 12-hour light-dark cycle and free access to food and water for three weeks (Fig. 1). This research was approved by the Biomedical Ethics Committee with code 003.1399 IR.IAU.IAUG.REC, ensuring that all ethical principles regarding laboratory animal handling were adhered to by the biomedical ethics committee guidelines throughout all stages of the experimental process.

Diabetes Induction and Experimental Design

Black seed extract was obtained via the percolation method. Diabetes was induced in the animals using streptozotocin (in powder form in 1 g vials, Sigma, USA). Various doses of the drug (60-70 mg/kg) were injected into the rats, and 72 hours post-administration, blood glucose levels were measured using a glucometer (Accu-Chek, Germany). Rats with fasting blood glucose levels of ≥ 200 mg/dl were classified as diabetic, ultimately determining 70 mg/kg as the effective dose for inducing diabetes. The animals were then randomly divided into seven groups of ten:

1. **Control Group:** Received no treatment.
2. **Solvent Group:** Received only the solvent of the extract.
3. **Experimental Groups 1 and 2:** Received hydroalcoholic black seed extract and honey (Dosin) at doses of 2 g/kg and 4 g/kg, respectively.
4. **Diabetic Control Group:** Received 70 mg/kg of streptozotocin intraperitoneally.
5. **Experimental Groups 4 and 5:** Received streptozotocin followed by the extracts at 2 g/kg and 4 g/kg, respectively.

The administration of the black seed extract (*N. sativa* L.) and honey was conducted *via* oral gavage for 21 consecutive days. Control samples were collected 24 hours after the last drug administration. Serum was prepared from blood samples after centrifugation (15 minutes at 5000 RPM) and stored at -20°C until thyroid hormone and blood glucose measurements were performed.

Preparation of Hydroalcoholic Black Seed Extract

For the preparation of black seed extract, 2 kg of black seed seeds were purchased and ground into powder. To prepare the hydroalcoholic extract, 800 mL of 70% ethanol was mixed with 200 g of the powdered plant. The dry plant powder was soaked at room temperature for 48 hours and then filtered twice through a porous cloth. The resulting solution was extracted using a rotary evaporator. Finally, the solution was placed in an incubator at 37°C to evaporate water and alcohol, leaving a concentrated yellow syrup. The extract was then mixed with 1.5 kg of honey. The hydroalcoholic black seed extract and honey (Dosin) were stored in a refrigerator, from which the necessary amounts were removed daily and administered orally to the experimental groups at 9 AM for 21 days.

Drug Administration and Blood Sampling

Following the preparation of the required drug amounts for the various experimental groups, the drugs were weighed using a digital scale with 0.001 g accuracy. After a 12-hour fasting period, streptozotocin (70 mg/kg) dissolved in physiological saline was injected intraperitoneally to induce diabetes. Fifty days post-injection, blood samples were obtained via the tail vein, and blood glucose levels were recorded. Additionally, blood samples were measured using a glucometer to confirm the diabetic status of the rats. Rats with blood glucose levels exceeding 200 mg/dl were classified as diabetic, while others were excluded from the study. The dose for streptozotocin was determined based on previous studies. For confirmation of sustained diabetes, an oral glucose

tolerance test (OGTT) was conducted after 14 days, wherein each rat was administered 1 g/kg of glucose orally. Blood glucose levels were measured at 10- and 60 minutes post-glucose administration. Concentrated extract at doses of 2 and 4 g/kg was prepared and administered daily to experimental groups 1, 2, 4, and 5 via gavage for 21 days. The hydroalcoholic black seed extract and honey (Dosin) were administered to the respective experimental groups at 9 AM using a special gavage needle, while the control group received distilled water, and the solvent group received normal saline. For the extract, the rats were positioned to keep their mouths open, ensuring the gavage needle was correctly placed in the esophagus before the solution was administered. After the study period, blood samples from the heart were gently transferred into labeled test tubes. The samples were left at laboratory temperature (37°C) for 20 to 30 minutes to allow clotting. Blood tests for all experimental animals followed the same procedure (Fig. 1). Subsequently, thyroid hormones and biochemical factors were measured using luminescence and autoanalyzer devices, model 2000-R, made in the USA. The autoanalyzer is designed to measure blood chemical compositions by mixing the sample with a reagent and measuring colorimetric reactions in a continuous flow system. Measurements are based on spectrophotometry, wherein the serum is treated with a specific reagent, resulting in a color change. According to Beer's law, the light absorbance is compared against a standard to determine the concentration of the target compound.



Fig. 1 Laboratory rat housing and blood sampling procedure

Thyroid Hormones (TSH, T3, T4) Measurement

For the measurement of thyroid hormones, including thyroid-stimulating hormone (TSH), triiodothyronine (T3), and thyroxine (T4), the serum samples were analyzed using an immunochemiluminescent assay (ICL) method. The assays were conducted with the luminescence device, utilizing specific kits from Pars Azmoon for TSH and Abbott for T3 and T4. Each kit was used according to the manufacturer's instructions, where serum samples were incubated with specific antibodies bound to magnetic beads, followed by the addition of a chemiluminescent substrate, allowing quantification of the hormone levels through light emission detection.

Cholesterol and Lipid Profile (Triglycerides, LDL, HDL) Measurement

Total cholesterol, triglycerides, low-density lipoprotein (LDL), and high-density lipoprotein (HDL) levels were quantified using the colorimetric method on the Siemens Advia 1800 analyzer. The lipid profile was assessed using the GPO-PAP method for cholesterol and triglycerides, with reagent kits from Randox laboratories. For HDL cholesterol, the precipitation method using the Polyelectrolyte precipitation kit from Merck was applied, while LDL was calculated using the Friedewald formula: $LDL = \text{Total cholesterol} - HDL - (\text{Triglycerides}/5)$. The methods were carried out following standard protocols, ensuring accuracy and reproducibility.

Albumin Measurement

Serum albumin was determined using the Bromocresol Green (BCG) dye-binding method, which was performed on the Beckman Coulter AU 480 analyzer. The serum samples were mixed with a BCG reagent, resulting in a color change proportional to the albumin concentration. The absorbance was measured at 630 nm, and the albumin levels were calculated based on a standard curve prepared with known albumin concentrations.

Total Protein Measurement

Total protein levels in serum were assessed using the Biuret method with the Cobra 6000 autoanalyzer (Cobra Biochemicals, USA). In this method, proteins in the serum react with copper ions in an alkaline solution to form a colored complex. The intensity of the color, measured at 540 nm, is directly proportional to the total protein concentration in the sample. The results were compared to a standard curve established with known protein concentrations.

Liver Tissue Sample Preparation

The rats were placed in a container containing cotton soaked with chloroform. After about 20 to 30 seconds, ensuring complete anesthesia, the rats were fixed on a dissection table with their limbs secured. The abdominal area was disinfected with alcohol and betadine, and the skin was incised with scissors, followed by the opening of the peritoneum. The liver was then quickly excised, rinsed in 70% alcohol, and transferred to a sterile plate. A 0.5 g sample of liver tissue was cut into small pieces using a scalpel and placed into 1.5 mL vials containing 1 mL of Trizol. The labeled vials were transported on ice to the laboratory. After performing the steps of fixation, dehydration, clearing, embedding, sectioning, and staining (using hematoxylin-eosin and trichrome stains), a tissue slide was prepared.

Statistical Analysis

The statistical analysis of the data collected in this study was conducted using IBM SPSS statistics software (version 19). To compare the means of biochemical parameters across the seven experimental groups, a one-way analysis of variance (ANOVA) was utilized. This method allows for the assessment of differences in means among multiple groups simultaneously. Before conducting the ANOVA, the assumptions of normality and homogeneity of variances were tested using the Shapiro-Wilk test and Levene's test, respectively. After confirming these assumptions, Tukey's Honestly Significant Difference (HSD) test was performed to identify specific differences between groups while controlling for Type I error rates in multiple comparisons. A significance level of $p < 0.05$ was set, indicating statistically meaningful differences among groups. The results were expressed as means \pm standard deviation (SD) for continuous variables. Additionally, graphical representations, including bar graphs,

were generated using Microsoft excel. This comprehensive statistical approach ensured a robust analysis and accurate interpretation of the biochemical effects of the treatments applied in this study.

RESULTS

The study investigated the therapeutic effects of hydroalcoholic extract of black seed (*Nigella sativa*) and honey on various biochemical parameters, thyroid hormones, and liver tissue in streptozotocin-induced diabetic male rats. The results are summarized in the following sections based on the data provided in the tables and figures.

Thyroid Hormone Levels and Biochemical Factors

Table 1 demonstrates significant changes in thyroid hormone levels (TSH, T3, and T4) and biochemical factors such as cholesterol, triglycerides, LDL, and HDL. Notably, groups treated with the hydroalcoholic extract of black seed and honey (Experimental groups 1 and 2) exhibited a significant reduction in triglycerides ($p < 0.05$) and LDL compared to the control and placebo groups. Furthermore, HDL levels were significantly increased in these treated groups, indicating an improved lipid profile. T3 levels were notably higher in experimental groups 4 and 5 (4 g/kg), while TSH levels were elevated in diabetic groups without significant treatment.

Table 1 Comparison of mean thyroid hormone levels, and some biochemical factors in streptozotocin-induced diabetic adult male rats

Treatments	TSH	T3	T4	Chl.	TG	LDL	HDL
Control	4.97 ± 0.18	1.38 ± 0.07	7.11 ± 0.14	61.56 ± 2.27	76.88 ± 4.66	16.13 ± 1.30	31.44 ± 0.89
Placebo	4.80 ± 0.13	1.40 ± 0.06	6.80 ± 0.14	64.44 ± 3.63	74.25 ± 4.05	18.13 ± 0.69	34.69 ± 1.13
Exp. 1	4.72 ± 0.14	1.37 ± 0.06	6.90 ± 0.12	77.45 ± 3.63 *	61.25 ± 4.05 *	24.13 ± 0.78 *	41.95 ± 2.14 *
Exp. 2	4.60 ± 0.16	1.35 ± 0.08	7.15 ± 0.13	76.19 ± 1.60 *	69.31 ± 6.31	24.75 ± 0.92 *	40.88 ± 2.23 *
Exp. 3	5.85 ± 0.08 *	1.37 ± 0.06	7.02 ± 0.14	88.25 ± 3.19 *	76.69 ± 4.65	25.25 ± 1.29 *	34.81 ± 1.48
Exp. 4	4.92 ± 0.09	1.73 ± 0.06 **	6.90 ± 0.06	81.94 ± 2.05 **	59.44 ± 3.60 **	23.75 ± 1.16	35.63 ± 1.42
Exp. 5	5.88 ± 0.08	1.73 ± 0.08 **	7.00 ± 0.08	73.44 ± 3.52 **	63.13 ± 3.84	25.13 ± 1.04	36.56 ± 1.51

TSH: Thyroid stimulating hormone, T3: Triiodothyronine, T4: Thyroxine, Chl.: Cholesterol, TG: Triglyceride, LDL: Low-density lipoprotein, HDL: High-density lipoprotein, Exp.: Experimental group, *: Indicates a significant difference between experimental groups 1, 2, and 3 with the control and placebo groups.

Liver and Body Weight

Table 2 reveals significant changes in liver and body weight across the groups. Rats treated with 4 g/kg of the extract (Experimental groups 4 and 5) showed a considerable increase in body weight ($p < 0.05$) compared to the control and placebo groups, indicating

better metabolic health. In contrast, the diabetic control group exhibited reduced liver weight, reflecting liver damage. The administration of black seed extract led to a significant reduction in liver weight loss and improved liver function, as evidenced by increased serum albumin and total protein levels.

Table 2 Comparison of mean of the albumin, protein, liver and body weights in streptozotocin-induced diabetic adult male rats

Treatments	ALB	Protein	Liver weight	Body weight
Control	3.14 ± 0.04	6.26 ± 0.12	9.42 ± 0.07	203.25 ± 2.83
Placebo	3.12 ± 0.04	6.31 ± 0.09	9.31 ± 0.05	204.87 ± 4.34
Exp. 1	3.32 ± 0.05	6.86 ± 0.11 *	7.86 ± 0.11 *	207.68 ± 3.31
Exp. 2	3.34 ± 0.04 *	6.81 ± 0.12 *	7.67 ± 0.14 *	206.25 ± 2.16
Exp. 3	3.61 ± 0.04 *	7.63 ± 0.14 *	5.86 ± 0.16 *	205.75 ± 3.22
Exp. 4	3.54 ± 0.03	7.71 ± 0.11	6.31 ± 0.12 **	229.5 ± 3.36 **
Exp. 5	3.04 ± 0.12 **	6.77 ± 0.07 **	6.92 ± 0.14 **	226.87 ± 4.32 **

ALB: Albumin, Exp.: Experimental group, *: Indicates a significant difference between experimental groups 1, 2, and 3 with the control and placebo groups.

Liver Tissue Damage

The assessment of liver tissue damage in streptozotocin-induced diabetic rats was a crucial part of the study. In the diabetic control group, severe liver damage was observed, characterized by extensive necrosis and inflammatory cell infiltration around the hepatic lobules. As shown in Table 3, necrosis affected up to 30-40% of the liver tissue in untreated diabetic rats, which is

indicative of the oxidative stress and inflammatory responses caused by hyperglycemia. Additionally, the mitotic rate (MR), which reflects the liver's attempt to regenerate damaged cells, was elevated in this group. The histopathologic subtype in most diabetic animals was nodular, suggesting significant structural alterations to the liver architecture, and further pointing to the severity of liver injury in diabetic conditions.

Table 3 Assessment of liver tissue damage in streptozotocin-induced diabetic adult male rats

CN	HPS	TMS (cm)	Clark's Level	Necrosis (%)	MR
Control	Nodular	0.4	V	About 10%	HPF > 20:10
Placebo	Nodular	0.6	V	About 30%	HPF > 20:10
Exp. 1	Nodular	1	V	About 30%	HPF > 20:10
Exp. 1	Nodular	0.9	V	About 5%	HPF > 20:10
Exp. 2	Nodular	0.7	VI	About 10%	HPF > 20:10
Exp. 2	Nodular	0.6	VI	30%	HPF > 20:10
Exp. 3	Nodular	1	VI	40%	HPF > 20:10
Exp. 3	Nodular	1	VI	30%	HPF > 20:10
Exp. 4	Nodular	1	VI	40%	HPF > 20:10
Exp. 4	Nodular	1	VI	40%	HPF > 20:10
Exp. 5	Nodular	1	VI	20%	HPF > 20:10
Exp. 5	Nodular	1	VI	30%	HPF > 20:10

CN: Case number, HPS: Histopathologic subtype, TMS: Tumour microscopic size, MR: Mitotic rate.

In contrast, experimental groups 1 and 2, which were treated with 2 g/kg and 4 g/kg of hydroalcoholic black seed extract and honey, showed markedly reduced levels of liver damage. Specifically, necrosis in these groups decreased to around 5-10%, as indicated in tables 3 and 4, highlighting the protective effects of the extract. The mitotic rate was also significantly lower, suggesting reduced cellular stress and a more stabilized liver function. These findings align with previous research on the hepatoprotective properties of *Nigella sativa* and honey, likely due to their antioxidant and anti-inflammatory effects, which reduce oxidative damage and promote tissue repair.

Histological Analysis

The histological analysis, based on the photomicrographs (Fig. 2), provided visual confirmation of the effects observed in the biochemical and tissue damage assessments. Figure 1A illustrates a normal hepatic lobule in the control group, where hepatocytes (H), sinusoids (S), and the central vein (CV) maintain their typical structural integrity. No signs of inflammation or cell death are visible, reflecting healthy liver tissue.

In figure 1B, the diabetic control group exhibits clear signs of inflammation, with a prominent accumulation of mononuclear cells and Kupffer cells (macrophages) around the central vein (thick black arrow). This inflammation is a direct result of hyperglycemia-induced oxidative stress, which leads to liver damage and impairs normal liver function. The histological changes in this group are consistent with the observed biochemical markers of liver injury, such as elevated liver enzymes.

Figures 1C and 1D show liver sections from the diabetic groups treated with 2 g/kg and 4 g/kg of black seed extract and honey, respectively. In both images, no signs of inflammation are visible, and the hepatocytes and central vein structures appear largely intact. The absence of cell accumulation around the central vein and the restoration of normal liver architecture in these groups indicate a significant anti-inflammatory and protective effect of the treatment. The histological evidence reinforces the conclusion that the hydroalcoholic extract of *Nigella sativa* and honey mitigates liver damage and supports hepatic recovery in diabetic rats, with the 4 g/kg dose showing the most substantial protective effects.

These results confirm the potential therapeutic role of black seed and honey in protecting liver tissue from diabetes-related damage.

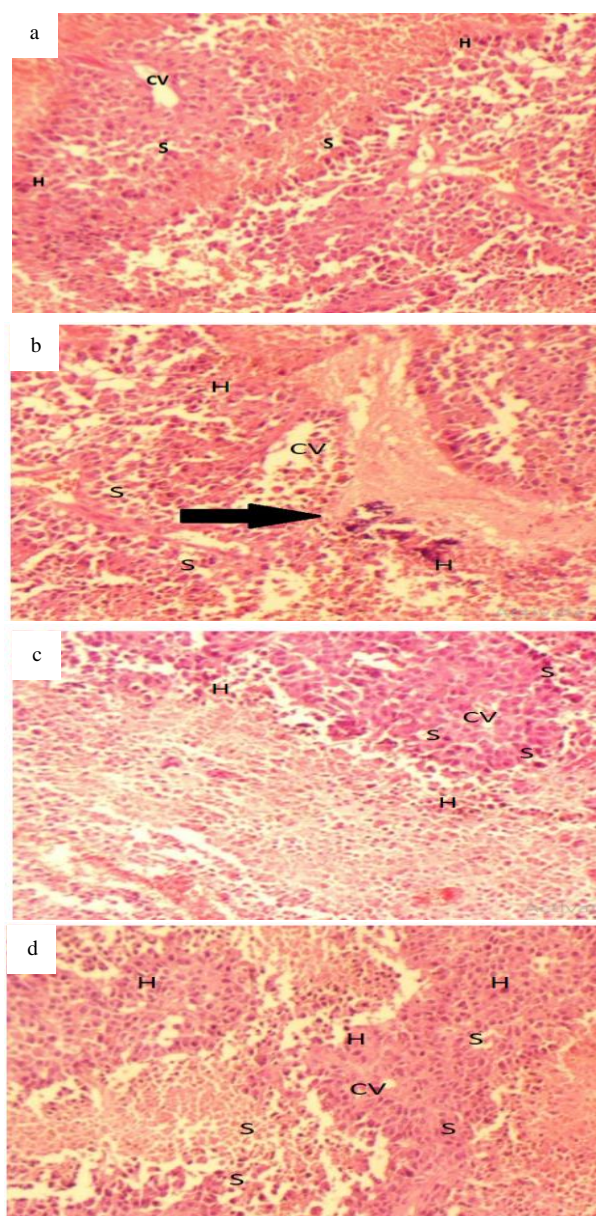


Fig. 2 A shows a photomicrograph of a hepatic lobule from the control group, where normal structure is observed, including hepatocytes (H), sinusoids (S), and a central vein (CV). B displays a cross-section from the diabetic control group, with evident inflammation as mononuclear cells and Kupffer cells (thick black arrow) accumulate around the central vein. In C, a section from the diabetic group treated with 2 g/kg hydroalcoholic extract shows no signs of inflammation, with no cell accumulation around the central vein. Similarly, D represents the diabetic group treated with 4 g/kg extract, where no inflammatory markers are observed, indicating enhanced protection.

Table 4 Assessment of liver tissue damage in streptozotocin-induced diabetic adult male rats (*continue*)

CN	RFP	TIL	VI	Microsatellites	Neurotropism
Control	Not seen	Not seen	Not seen	Not seen	Not seen
Placebo	Not seen	Not seen	Not seen	Not seen	Not seen
Exp. 1	Not seen	Not seen	Not seen	Not seen	Not seen
Exp. 1	Not seen	Not seen	Not seen	Not seen	Not seen
Exp. 2	Not seen	Not seen	Not seen	Not seen	Not seen
Exp. 2	Not seen	Not seen	Not seen	Not seen	Not seen
Exp. 3	Not seen	Not seen	Not seen	Not seen	Not seen
Exp. 3	Not seen	Not seen	Not seen	Not seen	Not seen
Exp. 4	Not seen	Not seen	Not seen	Not seen	Not seen
Exp. 4	Not seen	Not seen	Not seen	Not seen	Not seen
Exp. 5	Not seen	Not seen	Not seen	Not seen	Not seen
Exp. 5	Not seen	Not seen	Not seen	Not seen	Not seen

CN: Case number, RFP: Regressive fibrosis lymphocytes, TIL: Tumour infiltration lymphocytes, VI: Vascular invasion.

DISCUSSION

The findings of this study demonstrate the therapeutic potential of hydroalcoholic extract of black seed (*Nigella sativa*) and honey in mitigating the adverse effects of streptozotocin-induced diabetes on biochemical parameters, thyroid hormone levels, and liver tissue in adult male rats. The results reveal significant improvements in lipid profiles, liver function, and thyroid hormone regulation in the experimental groups treated with *Nigella sativa* and honey, highlighting the efficacy of these natural compounds in addressing diabetes-induced complications. The study observed significant improvements in cholesterol, triglyceride, LDL, and HDL levels in the groups treated with hydroalcoholic extract of black seed and honey, particularly at the 4 g/kg dose. These findings align with previous research reported that black seed extract effectively reduced fasting blood glucose and lipid levels in diabetic rats [17]. The reduction in LDL and triglycerides, combined with the increase in HDL, suggests that *Nigella sativa* and honey can positively influence lipid metabolism, reducing cardiovascular risk factors associated with diabetes. This is further supported by studies conducted by Barkas *et al.* (2016) and Mohamad *et al.* (2014), who demonstrated similar lipid-lowering effects in diabetic models [7, 20].

The ability of black seed extract and honey to modulate oxidative stress also contributes to improved lipid profiles. The antioxidant properties of thymoquinone, the active component of *Nigella sativa*, play a critical role in reducing reactive oxygen species (ROS) and preventing lipid peroxidation, which is consistent with findings by Newsholme *et al.* (2016) [9]. The anti-inflammatory effects of honey further complement this, providing a synergistic approach to lipid regulation and oxidative stress reduction. Thyroid hormone dysregulation is a common consequence of diabetes, often manifesting as subclinical hypothyroidism. In this study, the administration of black seed extract and honey significantly improved T₃ levels in the treated groups, particularly at the 4 g/kg dose. The findings support the hypothesis that these natural compounds can positively influence the hypothalamic-pituitary-thyroid (HPT) axis, which is frequently disrupted in diabetic conditions. Similar results were reported by Abdallah *et al.* (2016), who found that black seed extract improved thyroid function in diabetic models [21].

The observed increase in T₃ levels, coupled with the stabilization of TSH, suggests that *Nigella sativa* and honey may improve thyroid hormone regulation through their anti-inflammatory and antioxidant properties. This is in line with the work of Feldt-Rasmussen *et al.* (2021), who highlighted the role of oxidative stress in disrupting thyroid function in diabetic patients [10].

The liver plays a central role in glucose and lipid metabolism, making it highly susceptible to diabetes-induced damage. In this study, the diabetic control group exhibited significant liver damage, including necrosis and inflammation, as evidenced by histological analysis and elevated liver enzyme levels. However, the groups treated with black seed extract and honey showed remarkable improvements in liver function, with reduced necrosis and inflammatory cell infiltration. This hepatoprotective effect is supported by previous studies, such as those by Mohamed *et al.* (2016), which demonstrated that black seed oil and honey reduced liver damage in diabetic models by lowering oxidative stress and inflammation [22].

The anti-inflammatory effects of *Nigella sativa* are primarily attributed to thymoquinone, which has been shown to reduce liver inflammation and oxidative stress in diabetic rats. Honey's natural wound-healing properties and its ability to reduce inflammatory

cytokines further contribute to this protective effect, as shown in studies by Abdallah *et al.* (2016). The combination of these two natural compounds enhances their individual effects, resulting in a significant reduction in liver damage, as evidenced by the reduction in necrosis and improved liver architecture in the treated groups [21].

The findings of this study are consistent with those of Heshmati *et al.* (2015), who reported similar improvements in lipid profiles and liver function following treatment with *Nigella sativa* in diabetic models [17]. The synergistic effects of black seed and honey observed in this study also corroborate the work of Mohamad *et al.* (2014), who demonstrated that co-administration of these natural compounds yielded better glycemic control and lipid management than either treatment alone [20].

While the current study focused on diabetic rats, the observed improvements in biochemical parameters, thyroid function, and liver health align with findings from human studies. Salehi *et al.* (2021) reported that black seed supplementation improved lipid profiles and reduced markers of oxidative stress in diabetic patients. This suggests that the therapeutic potential of *Nigella sativa* and honey extends beyond animal models and may apply to human diabetes management [15].

CONCLUSION

In conclusion, the hydroalcoholic extract of black seed and honey demonstrated significant therapeutic effects on biochemical parameters, thyroid hormones, and liver tissue in streptozotocin-induced diabetic rats. These findings suggest that the combination of *Nigella sativa* and honey offers a promising natural treatment strategy for managing diabetes and its complications. The hepatoprotective, anti-inflammatory, and antioxidant properties of these compounds contribute to improved lipid profiles, thyroid hormone regulation, and liver function. Future studies should explore the molecular mechanisms underlying these effects and assess the potential for clinical application in human diabetic patients.

ACKNOWLEDGMENT

We would like to express our sincere gratitude to Kazerun Branch, Islamic Azad University for their invaluable support and special assistance. Their continuous encouragement and provision of resources have played a significant role in facilitating the completion of this scientific article. We deeply appreciate their commitment to advancing academic research and fostering a supportive environment for researchers.

REFERENCES

- Hossain M.J., Al-Mamun M., Islam M.R. Diabetes mellitus, the fastest growing global public health concern: Early detection should be focused. *Health Sci Rep.* 2024;7(3):e2004.
- Cusick M., Meleth A.D., Agrón E., Fisher M.R., Reed G.F., Knatterud G.L., Barton F.B., Davis M.D., Ferris III F.L., Chew E.Y. Associations of mortality and diabetes complications in patients with type 1 and type 2 diabetes: Early treatment diabetic retinopathy study report no. 27. *Diabetes Care.* 2005;28(3):617-625.
- Papathodorou K., Banach M., Bekiari E., Rizzo M., Edmonds M. Complications of diabetes 2017. *J Diabetes Res.* 2018;3086167.
- Mollaeian A., Roudsari H., Talebi E. Sweet's syndrome: A classical presentation of a rare disease. *J Investigative Med High Impact Case Rep.* 2019;7:2324709619895164.
- Haw J.S., Venkat Narayan K.M., Ali M.K. Quality improvement in diabetes—successful in achieving better care with hopes for prevention. *Annals of the New York Academy of Sciences.* 2015;1353(1):138-151.

6. Pandey A., Chawla S., Guchhait P. Type-2 diabetes: Current understanding and future perspectives. *IUBMB Life*. 2015;67(7):506-13.
7. Barkas F., Elisaf M., Liberopoulos E., Liontos A., Rizos E.C. High triglyceride levels alter the correlation of apolipoprotein B with low- and non-high-density lipoprotein cholesterol mostly in individuals with diabetes or metabolic syndrome. *Atherosclerosis*. 2016;247:58-63.
8. Kaur J., Singh P., Sowers J.R. Diabetes and cardiovascular diseases. *American Journal of Therapeutics*. 2002;9(6):510-515.
9. Newsholme P., Cruzat V.F., Keane K.N., Carlessi R., de Bittencourt Jr P.I.H. Molecular mechanisms of ROS production and oxidative stress in diabetes. *Biochemical J*. 2016;473(24):4527-4550.
10. Feldt-Rasmussen U., Effraimidis G., Klose M. The hypothalamus-pituitary-thyroid (HPT)-axis and its role in physiology and pathophysiology of other hypothalamus-pituitary functions. *Mol Cell Endocrinol*. 2021;525:111173.
11. Fekete C., Lechan R.M. Central regulation of hypothalamic-pituitary-thyroid axis under physiological and pathophysiological conditions. *Endocrine Rev*. 2014;35(2):159-194.
12. Stefan N., Cusi K. A global view of the interplay between non-alcoholic fatty liver disease and diabetes. *The Lancet Diabetes Endocrinol*. 2022;10(4):284-296.
13. Talebi E., Rowghani Haghighi Fard E., Navabi M., Eatemadi M. Evaluating the effect of two types of thyme essential oils (*Zataria multiflora* and *Ziziphora clinopodioides lam*) on some productive traits and blood parameters in broilers. *Poultry Sci J*. 2021;9(1):107-119.
14. Nasrollahi I., Talebi E., Nemati Z. Study on *Silybum marianum* seed through fatty acids comparison, peroxide tests, refractive index and oil percentage. *Pharmacog J*. 2016;8(6).
15. Salehi B., Quispe C., Imran M., Ul-Haq I., Živković J., Abu-Reidah I.M., Sen S., Taheri Y., Acharya K., Azadi H., del Mar Contreras M. *Nigella* Plants – traditional uses, bioactive phytoconstituents, preclinical and clinical studies. *Frontiers in Pharmacology*. 2021;12:1-26.
16. Dalli M., Bekkouch O., Azizi S.E., Azghar A., Gseyra N., Kim B. *Nigella sativa* L. phytochemistry and pharmacological activities: A Review (2019–2021). *Biomolecules*. 2022;12(1):20.
17. Heshmati J., Namazi N. Effects of black seed (*Nigella sativa*) on metabolic parameters in diabetes mellitus: A systematic review. *Complementary Therapies in Medicine*. 2015;23(2):275-282.
18. Mohit M., Farrokhzad A., Faraji S.N., Heidarzadeh-Esfahani N., Kafeshani M. Effect of *Nigella sativa* L. supplementation on inflammatory and oxidative stress indicators: A systematic review and meta-analysis of controlled clinical trials. *Complementary Therapies in Med*. 2020;54:1025-1035.
19. Alzahrani H., Bakhotmah B., Boukraâ L. In Vitro susceptibility of diabetic wound bacteria to mixtures of honey, *Commiphora molmol* and *Nigella sativa*. *The Open Nutraceuticals J*. 2011;4(1).
20. Mohamad S., Ibrahim N.H., Yusof H. Blood pressure and lipid lowering effects of *Nigella sativa* seeds and honey mixture. *Journal of Nursing and Health Science*. 2014;3(1):89-96.
21. Abdallah M., Ali M., Kelany M. Antioxidant and antiapoptotic effects of combined Sidr honey and *Nigella sativa* oil against paracetamol-induced hepato-nephrotoxicity in rats. *Zagazig University Medical Journal*. 2016;22(1):1-12.
22. Mohamed J., Nazratun Nafizah A.H., Zariyantey A.H., Budin S.B. Mechanisms of diabetes-induced liver damage: The role of oxidative stress and inflammation. *Sultan Qaboos Univ Med J*. 2016;16(2):e132-141.