

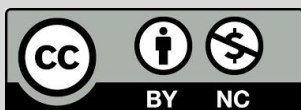## Review Article

# An Overview of Monkey Pox Disease as a Current Important Disease in the World

Soleimani, S<sup>1\*</sup>, Motamed, N<sup>1</sup>

1. Razi Vaccine & Serum Research Institute, Agricultural Research Education and Extension Organization (AREEO), P.O. Box 31975-148, Karaj, Iran.

**How to cite this article:** Soleimani S, Motamed N. An Overview of Monkey Pox Disease as a Current Important Disease in the World. *Archives of Razi Institute*. 2024;79(6):1121-1133. DOI: [10.32592/ARI.2024.79.6.1121](https://doi.org/10.32592/ARI.2024.79.6.1121)



Copyright © 2023 by



Razi Vaccine & Serum Research Institute

## ABSTRACT

Monkey pox has recently garnered significant attention due to the proliferation of re-emerging and emerging infectious diseases, particularly epidemic-scale outbreaks. Mpox was initially identified as a discrete illness in 1958 among laboratory monkeys in Copenhagen, Denmark. The initial case of monkey pox infection in humans was documented in 1970 in the Democratic Republic of the Congo. The patient was a nine-month-old boy who was the sole member of his family to lack smallpox vaccination. The monkey pox virus is a zoonotic virus belonging to the family Poxviridae, subfamily Chordopoxvirinae, and genus Orthopoxvirus. Transmission of monkey pox occurs via direct contact with an infected individual or surface. Additionally, transmission between humans can occur via the bodily fluids of an infected individual. This review article addresses all aspects of this disease, beginning with an introduction, history, virology, clinical features, and complications. It then turns to clinical differential diagnosis with similar diseases, epidemiology, prevalence, animal hosts, virus transmission, disease diagnosis, prevention and treatment, and finally, future risks. In light of the aforementioned considerations, this article presents a comprehensive review of the various facets of the disease, offering a valuable resource for researchers and policymakers in the domains of health and public health. The article's insights into the disease's characteristics, its impact on human and animal health, and its potential as a zoonotic disease underscore the importance of disease prevention.

**Keywords:** *Monkey, Pox, Disease, Zoonosis, Epidemiology, Vaccine.*

### Article Info:

Received: 18 November 2024

Accepted: 12 October 2024

Published: 31 December 2024

**Corresponding Author's E-Mail:**

[s.soleimani@rvsri.ac.ir](mailto:s.soleimani@rvsri.ac.ir)

## 1. Context

Monkeypox, now designated Mpox, is an infectious viral disease that causes disease in humans and some animals. The first description of monkeypox was published in 1958, following the observation of the disease among monkeys that had been shipped from Singapore to Denmark. Subsequently, over the following decade, further outbreaks were documented in captive monkeys in the USA, the Netherlands, and France. The initial case of monkeypox infection in humans was documented in 1970 in the Democratic Republic of the Congo. The affected individual was a 9-month-old boy who was the sole member of his family to have not received the smallpox vaccination. Since the initial detection of the disease in a human case in the Democratic Republic of the Congo, there have been isolated instances of infection and outbreaks, predominantly confined to select countries in west and central Africa. The disease was named thus because it was first diagnosed in laboratory monkeys. However, given that the monkey was not the primary host of the disease, this nomenclature was subsequently called into question. In November 2022, the World Health Organization (WHO) announced its intention to adopt the term "Mpox" in its communications, urging other organizations to follow this recommendation (1). This disease is, in fact, a rare viral illness that initially presents with mild symptoms akin to those observed in chickenpox or influenza. The initial symptoms manifest as skin rashes and the appearance of pox lesions, which subsequently spread to the face and, in some cases, the entire body. The symptoms include the formation of blisters on the skin, which subsequently crust over, as well as a fever and the presence of swollen lymph nodes. The Mpox illness is typically mild, with the majority of infected individuals recuperating within a few weeks without treatment. Nevertheless, cases may be severe, particularly in children, pregnant women, or individuals with immunosuppression. In the wake of the alarming situation and the problems that have arisen with the sudden spread of the corona virus worldwide, attention has now turned to monkey pox, a virus that has caused significant concern for the WHO. The monkeypox virus is transmitted via direct contact with an infected individual or surface. Furthermore, human-to-human transmission can occur via sexual fluids and other bodily fluids of the infected individual. The incubation period for this virus, defined as the interval between infection and the onset of symptoms, typically ranges from six to 13 days. However, it can extend from five to 21 days (2). The disease is caused by the monkeypox virus, a zoonotic virus belonging to the Poxviridae family and the Orthopoxvirus genus. Additionally, the variola virus, which causes smallpox, vaccinia, cowpox, and camelpox, is included in this genus. The virus has the potential to disseminate from infected animals through the handling of infected meat or via bites or scratches. The subtypes of mpox virus, which will be elucidated in this article, were renamed in August 2022 in response to requests from numerous public health organizations and researchers.

These parties asserted that the former geographical names were impeding efforts to contain the disease. The clade previously designated as Congo Basin (Central African) has been renamed as Clade I, while the clade previously identified as West African has been designated as Clade II.

## 2. Data Acquisition

Mpox was initially identified as a distinct illness in 1958 among laboratory monkeys in Copenhagen, Denmark. The initial documented in human cases occurred in 1970, involving six unvaccinated children during the smallpox eradication efforts. The first case was that of a nine-month-old boy in the Democratic Republic of the Congo (DRC). Prior to 1970, the occurrence of the virus was only documented in non-human hosts (2). During the five-year period from 1981, more than 300 cases of this disease were reported in this country, primarily due to contact with animals. The virus has been detected in Gambian pouched rats, dormice, and African squirrels, which are often used as food. A significant increase in the number of mpox cases has been observed in central and west Africa, particularly in the Congo, where 2,000 cases per year were recorded between 2011 and 2014 (3). Initially, this disease was believed to be uncommon in humans. However, there has been an increase in cases since the 1980s, which may be attributed to a reduction in immunity following the discontinuation of smallpox vaccination. The global outbreak of clade II in 2022–2023 marked the inaugural instance of extensive community transmission beyond the African continent. In July 2022, the World Health Organization (WHO) designated the outbreak as a Public Health Emergency of International Concern (PHEIC). In May 2023, the WHO rescinded this designation as the outbreak was brought under control, citing a combination of vaccination and public health information as the successful control measures. On August 14, 2024, the World Health Organization (WHO) declared this outbreak a Public Health Emergency of International Concern (PHEIC). In its latest statement, the WHO has indicated that there is a high probability of further imported cases of the disease being registered in Europe in the coming days and weeks. A novel variant of clade I mpox virus (designated as clade Ib) was identified in the Democratic Republic of the Congo during 2023. As of August 2024, the virus has spread to several countries in the African region, including those outside of the Central African region (Cameroon, Central African Republic (CAR), Democratic Republic of the Congo, Gabon, and Republic of the Congo). This raises concerns that the virus may have adapted to more sustained human transmission.

### 2.1. Virology

The mpox virus is a zoonotic virus belonging to the Poxviridae family, Chordopoxvirinae subfamily, and Orthopoxvirus genus. It is a linear double-stranded DNA virus with a genome size of 197 kilobases. It is estimated that mpox encodes approximately 200 proteins. This virus

is classified within the Poxviridae family, which has been identified by the World Health Organization (WHO) as a group of pathogens with the potential to cause epidemics or pandemics. The subset comprises the variola, vaccinia, and cowpox viruses (Figure 1). The human mpox virus is an oval-shaped virus with a length of 220 to 450 nm, larger than viruses such as HIV or SARS-CoV-2. It is brick-shaped, enveloped, and cytoplasmic, binding to glycosaminoglycans to enter host cells (7). As an enveloped virus, it has been postulated to alternatively employ the classical apoptotic mimicry mechanism for entry into host cells (8). Recent bibliometric analyses have revealed a scarcity of literature pertaining to the pathogenesis, origins, and treatment of the human mpox virus (9). This is a matter of significant concern, given that the virus is classified as a Biosafety Level 3 (high-threat) pathogen in the EU and is included on the list of select agents in the United States (Central African clade). It has been demonstrated that MPXV virions (clade II) can be recovered from stainless steel discs after an extended period of time, including up to 30 days when stored at 4°C (10, 11). Two principal categories of virus are distinguished by differences in their genomes, which exhibit a divergence of less than one percent. These are designated as clade I and clade II. Clade I is associated with more severe disease and higher mortality rates. Some outbreaks of this particular strain of monkey pox virus have resulted in mortality rates as high as 10 percent among infected individuals. However, recent outbreaks have demonstrated lower mortality rates. Clade I is indigenous to Central Africa. The Mpox Clade II is the variant that caused the 2022 monkey pox outbreak. Infection with Clade II is less severe, with a survival rate exceeding 99.9% in infected individuals. Clade II is endemic to West Africa. Following the identification of a novel variant in April 2024, the clade I was subdivided into subclades designated Ia and Ib. Similarly, Clade II is divided into two subclades: Clade IIa and Clade IIb. It is estimated that Clade I is associated with a more severe disease course and higher mortality compared to Clade II (12).

## 2.2. Clinical Features and Complications

The initial indications of mpox infection include muscular discomfort, elevated body temperature, and sore throat, accompanied by headache, pruritus or pain in the affected area, lymphadenopathy, and fatigue. It is not obligatory for patients to exhibit all of the aforementioned symptoms in their entirety. The majority of patients exhibit symptoms between four and 11 days post-infection, although the incubation period can extend up to one day. The 2022-2023 outbreak demonstrated that the incubation period of the disease can range from 21 days to four weeks. The rash is characterised by the presence of numerous small lesions, which may manifest on the palms of the hands, soles of the feet, mouth, face, throat and genitals. In rare instances, the lesions may become necrotic, necessitating debridement and a longer healing period. The symptoms typically persist for a period of two to four weeks; however, in patients with

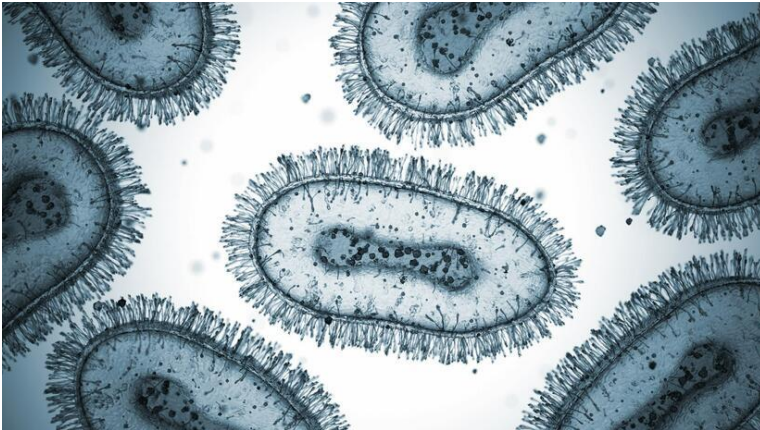
compromised immune systems, they may extend beyond this timeframe. As illustrated in Figure 2, the progression of lesions through several stages prior to falling off is a process delineated by the Center for Disease Control and Prevention. The progression of lesions through the various stages is as follows:

- Macular stage (flat loss)
- Papule (well-defined skin bump)
- Vesicle (blister, usually filled with clear fluid)
- Pustule (protrusion containing liquid and pus)
- Dried scab (14)

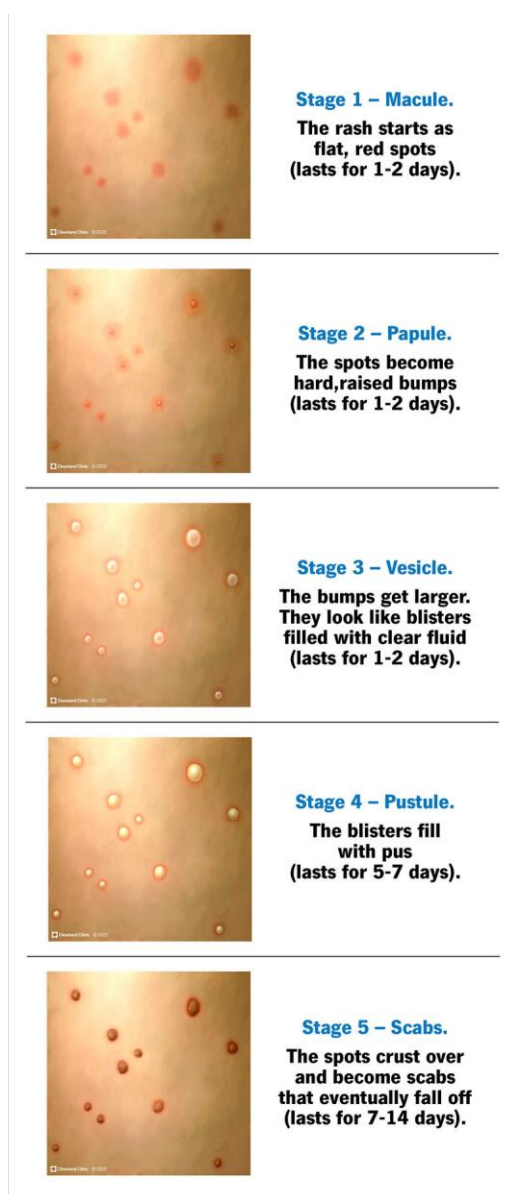
The disease is currently known to exist in two forms. The first, which has been in existence since 1970, is the classic form. The second, which has been proposed since 2022, is the new clinical-epidemiological form. The most significant distinctions between these two forms are in their respective locations, epidemiological characteristics, and viral types, as outlined in the recently proposed classification of the new clade 3 virus (Clade IIb). The mpox genome sequences of the 2022 cases, which we refer to as clade 3, have been determined to originate from the West African clade (lineage B.1) (13). Complications of monkeypox include secondary infections following the disease, sepsis, pneumonia, encephalitis, and vision loss due to corneal infection. The probability of developing a severe case of this disease is higher in individuals with a weakened immune system, whether due to medication, medical conditions, or the occurrence of diseases such as AIDS. Additionally, a history of eczema and children less than one year old are also risk factors. Infection with this agent during pregnancy may result in abortion or other complications (15). The case fatality rate (CFR) of this disease is estimated to be between 1% and 10%. Clade I is considered to be more severe than clade II. The mortality rate from global outbreaks in 2022 and 2023 caused by clade IIb was notably low, estimated at 0.16%. Additionally, the majority of fatalities occurred in individuals with compromised immune systems (16).

## 2.3. Symptoms Compared To Similar Diseases

The primary distinction between monkeypox and smallpox is the type of symptoms exhibited and the incidence of certain symptoms. One of the most distinctive characteristics of monkeypox is the enlargement of lymph nodes in various locations throughout the body, which typically manifests shortly after the onset of the disease. This swelling is the result of the body's natural immune response to a viral infection and may manifest in various locations, including the neck, armpits, and groin. In contrast to smallpox, which is typically associated with extensive and more severe cutaneous manifestations, monkeypox, particularly in its initial stages, is accompanied by more pronounced glandular symptoms, inflammation, and discomfort in the lymph nodes. These distinctions facilitate the early identification of the disease and have a substantial influence on the treatment and management of patients (17). It is therefore crucial to accurately identify these symptoms and differentiate them from one another in order



**Figure 1.** mpox virus



**Figure 2.** A visual review of Mpox stages

to diagnose the disease as accurately as possible and implement appropriate treatment measures. It is recommended that patients infected with monkeypox adhere to a rigorous symptom monitoring regimen under the guidance of a qualified medical professional, as this allows for prompt identification of potential complications and the implementation of necessary treatment measures. The distinguishing factor between monkeypox and chickenpox is the presence of specific symptoms that can facilitate the identification of the monkeypox. It is noteworthy that symptoms such as a runny nose and cough are typically absent in this disease. This distinguishes monkeypox from numerous other respiratory illnesses. In general, patients with monkeypox may present with symptoms such as fever, fatigue, muscle aches, and skin rashes, which typically manifest gradually on the body. These characteristics can assist medical professionals in diagnosing the disease, underscoring the importance of being aware of the specific symptoms associated with this infection (18). Both monkeypox and chickenpox are characterized by the development of cutaneous lesions; however, the viruses that cause these diseases are distinct. Both viruses can be transmitted via direct skin-to-skin contact or prolonged face-to-face contact. However, chickenpox is highly contagious and spreads more readily than mpox. The presence of swollen lymph nodes is more prevalent among individuals infected with mpox than those infected with chickenpox. The symptoms of chickenpox, including the rash, typically resolve within two weeks, whereas those of mpox may take two to four weeks to resolve. It is important to note that both monkeypox and plague are common infectious agents between humans and animals. Furthermore, both diseases can be effectively treated with vaccines. A further similarity between these two diseases is the manner of their transmission to humans, which occurs via respiration and contact. The etiological agent of monkeypox is a virus that is transmitted to humans through monkeys, whereas the etiological agent of plague is an infectious bacterial disease caused by the gram-negative bacterium *Yersinia pestis*. Additionally, the plague disease is primarily transmitted to humans through the body fleas of infected mice (19).

## 2.4. Epidemiology

The initial identification of human cases occurred in 1970 in Zaire (presently designated as the Democratic Republic of Congo, or DRC). Since that time, there has been a notable increase in the number of cases reported in humans, particularly in the Democratic Republic of Congo (DRC), which has documented cases on an ongoing basis. This increase in cases may be attributed to the cessation of smallpox vaccination (which provided some cross-protection) or waning immunity, environmental factors (e.g., increased population density, human settlements in unknown animal reservoirs, deforestation), and/or genetic evolution of the virus. Nevertheless, there is no evidence to substantiate these hypotheses (20). The disease was previously known to be endemic to Central and Western Africa. The majority of cases were reported in rural areas (adjacent to or within tropical forests) of the Congo Basin and western Africa, particularly in the DRC, where a major outbreak occurred from 1996 to 1997. Between 2000 and 2021, there were 95 suspected and 40 confirmed outbreaks in the Central African Republic, with the number of outbreaks increasing after 2018 (21). In 2017, Nigeria witnessed a resurgence of cases attributed to the clade II virus, marking the first instance of reported cases in 39 years. Subsequently, five further outbreaks have occurred between 2017 and 2021. The most significant outbreak of confirmed cases in the Central African Republic occurred in November 2021, with 14 documented cases and four documented instances of interhuman transmission. The initial identification of a global outbreak occurred in May 2022, and it has persisted since that time. A number of clusters of cases have been reported in several countries outside of Africa, despite the absence of direct travel links to endemic areas. This marked the first instance of chains of transmission being documented in countries lacking known epidemiological links to West and Central Africa. In July 2022, the World Health Organization (WHO) designated the 2022 global outbreak as a Public Health Emergency of International Concern (PHEIC). The PHEIC was lifted in May 2023, as the frequency of cases had decreased significantly, although cases continue to be reported. The majority of the variants currently circulating in the outbreak belong to the clade IIb of the monkeypox virus (22). Since the beginning of 2022, there have been over 99,000 confirmed cases of the disease reported globally from 116 countries, with 208 deaths as of June 30, 2024. The number of cases reached its highest point in August 2022 and has since exhibited a gradual decline. The countries most severely affected by the pandemic include the United States, Brazil, Spain, France, and Colombia (23). In locations where transmission had previously ceased, sporadic case clusters have been reported. In contrast to previous outbreaks, cases outside of Africa have been predominantly observed in younger adult males, the majority of whom identify as gay, bisexual, or other men who have sex with men. There is no evidence to suggest that sustained transmission outside of these networks is

occurring. The demographic most affected is males between the ages of 18 and 44 years (23). Additionally, cases have been documented in women (including pregnant women) and children, albeit with a lower frequency (24). In the United States, 2.7% of all reported cases were in women, including 3% in pregnant or recently pregnant women (as of November 2022). Transgender and gender-diverse individuals have been subjected to a greater degree of impact during the course of the outbreak (25). Additionally, disparities based on race and ethnicity have been observed (26). Adults aged 50 years and above appear to have a similar risk of hospitalization and death compared to adults below the age of 50. This may be attributed to the fact that older adults received the smallpox vaccine as part of their childhood immunization schedule (27). As of June 30, 2024, 4,232 confirmed cases and 35 confirmed deaths have been reported in Africa as part of the outbreak that began in early 2022. This represents 4% and 17% of the total number of global cases and deaths, respectively. The demographic characteristics of cases have been comparable to those observed in recent previous outbreaks in Africa, but markedly disparate from those seen in other regions. Specifically, 53% of cases have been identified in males with a median age of 17 years, and there is currently no available data on sexual transmission or exposure settings (23). It is noteworthy that the number of confirmed cases reported is considerably lower than the number of suspected cases. In Nigeria, the number of cases among children and women was higher than in other demographic groups, while the number of cases among people without HIV infection and gay, bisexual, or other men who have sex with men was lower than in countries outside of Africa. Furthermore, hospitalization rates were markedly elevated in comparison to other countries. Additionally, outbreaks due to the clade I virus occurred in refugee camps in the Republic of Sudan in 2022, with no evidence of a zoonotic origin (28). There has been a notable surge in the number of cases and fatalities in the DRC throughout 2023 and 2024, accompanied by an expansion of the geographic range into previously unimpacted regions, including neighboring countries such as Burundi, Kenya, Rwanda, and Uganda. Additionally, the clade Ib virus, a newly identified variant, has been documented for the first time in cases of sexual transmission (23). The outbreak persists, with sustained community transmission driven by sexual transmission. It remains unclear whether the currently circulating clade Ib variant is more transmissible or causes more severe disease than other clade I variants.

## 2.5. Prevalence

It is crucial to acknowledge that, regardless of geographical location, epidemiological context, biological sex, gender identity, or sexual orientation, the level of risk for individuals is primarily determined by personal factors such as exposure risk and immune health. The mpox virus was initially identified in monkeys in Denmark in 1958 during research activities. The initial case of mpox in a human being was reported in a nine-month-old boy in the

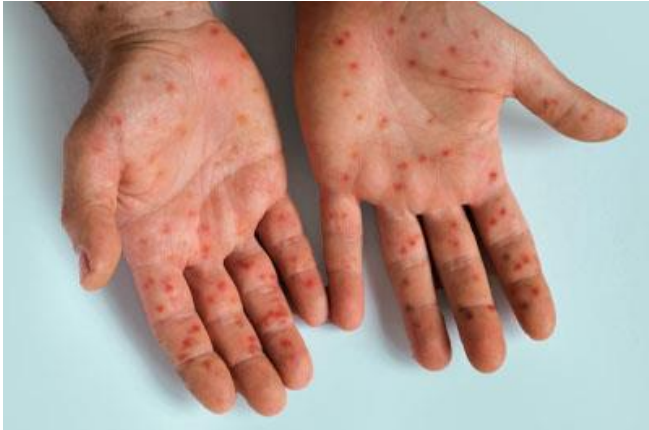Democratic Republic of the Congo in 1970. Following the global eradication of smallpox in 1980 and the subsequent cessation of smallpox vaccinations, there was a gradual resurgence of mpox in central, eastern, and western Africa. Subsequently, isolated instances of mpox have been recorded in central and eastern Africa (clade I) and western Africa (clade II). An outbreak in the United States in 2003 was associated with imported wild animals belonging to clade II. From 2005 onwards, the Democratic Republic of the Congo has reported thousands of cases annually. A study conducted between 2010 and 2019 revealed that the median age of MPX cases increased from four years old in the 1970s to 21 years old (30). In 2017, there was a resurgence of mpox in Nigeria, which has continued to disseminate among the population and through travelers to other regions. The data on suspected and confirmed cases up to 2021 can be accessed via a single link, while the data on laboratory-confirmed cases from 2022 to the present can be found in another. In May 2022, a sudden outbreak of mpox emerged and rapidly spread across Europe, the Americas, and all six WHO regions, primarily affecting (but not limited to) gay, bisexual, and other men who have sex with men, with transmission occurring mainly through sexual networks. In 2022, outbreaks of mpox caused by clade I were documented in refugee camps in the Republic of Sudan. Since 2022, there has been a notable increase in mpox cases and fatalities in the Democratic Republic of the Congo. This has been attributed to the emergence of a new variant of clade I, designated as clade Ib, which has been observed to spread person-to-person in certain regions. By mid-2024, this clade had also been identified in other countries. From January 2022 to August 2024, over 120 countries reported cases of mpox, with more than 100,000 laboratory-confirmed cases and over 220 deaths among confirmed cases. On two occasions, WHO Director-General Dr. Tedros Adhanom Ghebreyesus has designated mpox a public health emergency of international concern (PHEIC). The initial declaration was made in May 2022, with a subsequent declaration occurring in August 2024. The Democratic Republic of Congo is currently experiencing two discrete outbreaks of the monkeypox virus (MPXV). One outbreak involves the spread of MPXV clade Ia in the Equateur region and other endemic areas of the country, while the other involves the emergence of a new clade, clade Ib, in the South and North Kivu provinces. In August 2024, the World Health Organization (WHO) conducted a global risk assessment for monkeypox. The findings indicate the following levels of risk:

- In the eastern Democratic Republic of the Congo and neighboring countries, the overall risk is considered to be high.
- In regions of the Democratic Republic of the Congo where the monkeypox virus is endemic, the risk is similarly assessed as high.

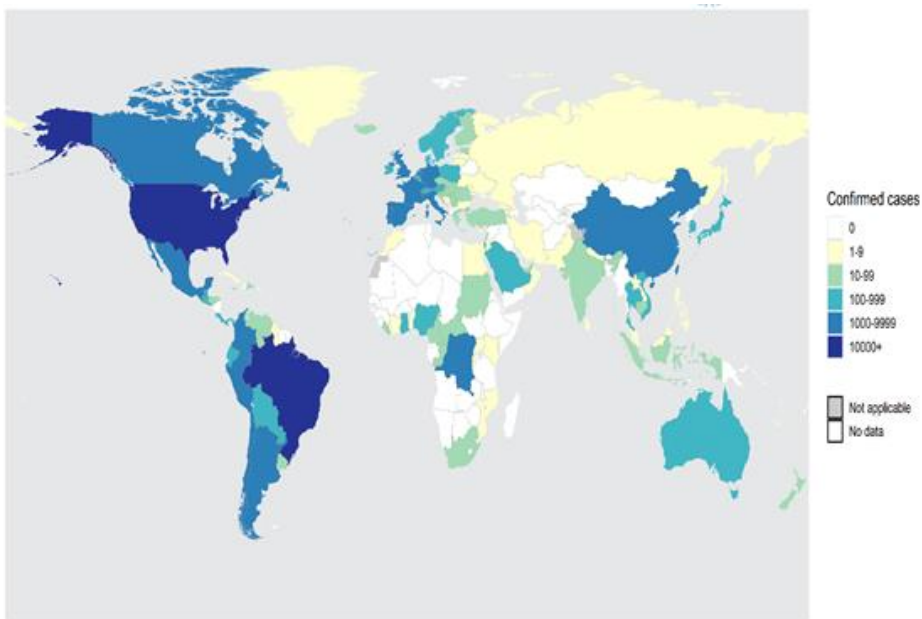
- In Nigeria and other countries in West, Central, and East Africa where mpox is endemic, the risk is considered to be moderate.
- In all other countries in Africa and worldwide, the risk is classified as moderate.

As of January 1, 2022, 121 Member States from all six WHO regions have reported cases of mpox. As of July 31, 2024, the World Health Organization (WHO) has documented a total of 102,997 laboratory-confirmed cases, 186 probable cases, and 223 deaths (Figures 3 and 4). In July 2024, the number of new cases reported monthly increased by 8.8% compared to the previous month. The majority of cases in the previous month originated from the African Region (54.9%) and the Region of the Americas (24.2%). The ten countries most affected by the disease since January 1, 2022, are as follows: The United States has the highest number of cases, with 33,556 reported cases, followed by Brazil (11,841), Spain (8,104), the Democratic Republic of the Congo (4,385), France (4,283), Colombia (4,256), Mexico (4,132), the United Kingdom (4,018), Peru (3,939), and Germany (3,886). Collectively, these nations account for 80% of the global number of reported cases. In the most recent reporting period, 22 countries observed an increase in the number of cases. A total of 35 countries have reported cases over the course of the past month. In the preceding month, no countries reported the occurrence of the first case of mpox. At present, there is no evidence to suggest that transmission is occurring outside of these networks on a sustained basis. The confirmation of even a single case of mpox in a country is considered to be an outbreak. Global aggregated data are collated via direct submissions from Member States to the World Health Organization (WHO) and its associated partners, or alternatively, via official country sources. The accompanying epidemic curve illustrates the aggregated number of cases by month, based on the date of case reporting. Iran is situated in the Middle East, surrounded by low-income countries with significant health challenges that not only affect their own populations but also have ramifications for neighboring countries. As indicated in the WHO reports, there have been fewer than 10 confirmed cases of mpox in Iran (Figure 3). The initial confirmed case of mpox in Saudi Arabia was reported on July 14, 2022, in Riyadh. By the end of 2023, there were eight active cases of the disease in Saudi Arabia. In 2022, five of the six Gulf Cooperation Council (GCC) countries—Bahrain, Kuwait, Oman, Qatar, and Saudi Arabia—documented a total of 30 cases of mpox. Notwithstanding the robust healthcare systems in place, these nations are susceptible to mpox due to a number of factors. These include the influx of travelers from regions experiencing outbreaks, forthcoming international events, and the possibility of continued transmission within the affected countries (31). Afghanistan is classified as a low-income country facing significant challenges, including a fragile healthcare system and a significant displacement crisis. These factors contribute to the difficulty of controlling communicable diseases and

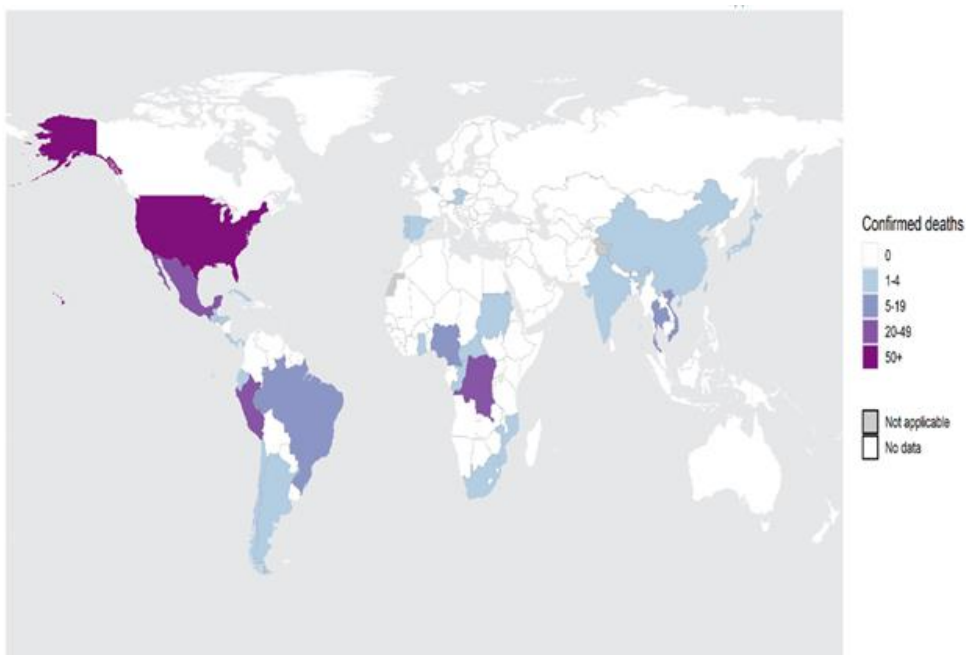




**Figure 3.** mpox symptoms



**Figure 4.** Total mpox cases from 1 Jan 2022 as of 31 Jul 2024



**Figure 5.** Total Mpox deaths from 1 Jan 2022 as of 31 Jul 2024

increasing the country's vulnerability to potential outbreaks of mpox. In order to mitigate the impact of any future mpox outbreak, it is essential that both the country in question and international stakeholders develop a preparedness plan that is focused on improving healthcare access. Thus far, there have been no confirmed cases of mpox in Afghanistan. Nevertheless, the dearth of high-quality, real-time surveillance data precludes an accurate estimation of the actual health burdens in the country (32). The initial case in Turkey was identified at the conclusion of June 2022. It has been reported that the patient is 37 years old and has an immune system deficiency caused by the HIV virus. At least 63 other cases have been confirmed in Turkey before late 2023, which raises significant concerns about the potential spread of the disease. Turkey is located between European countries, which have been particularly affected, and Asian countries, where the disease has not yet emerged. However, according to the Iraqi Ministry of Health, there have not been any monkeypox cases in the country yet. Pakistan has confirmed a second case of mpox in the Khyber Pakhtunkhwa (KP) province, as of late August 2024. The individual, who had traveled from a Gulf country, was transported to a medical facility in Peshawar. Since 2022, Pakistan has documented a total of 12 mpox cases, including one fatality, and at least three cases from the UAE, which is in close proximity to Iran. Monkey pox has demonstrated the potential to become a significant global public health concern over the past several years, with isolated outbreaks having been documented. On August 15, 2024, Sweden confirmed its first case of mpox clade I, a variant of the mpox disease that is well-known for its higher pathogenicity and transmission rate through close contact. This marks the inauspicious identification of this specific strain outside of the African continent. The Swedish government has indicated that additional cases are anticipated in the region in the near future. It is anticipated that the ongoing epidemic will continue to spread gradually over the coming months. It is imperative that prompt and efficacious measures be taken to manage the outbreak. In light of past epidemics, it is imperative that resources be shared in a timely and efficient manner (35).

#### 2.6. Animal Host Range

The mpox virus and the disease caused by this virus have been identified in a wide range of animals including monkeys, dormice (*Graphiurus* spp.), Gambian pouched rats (*Cricetomys gambianus*), anteaters, hedgehogs, prairie dogs, squirrels, shrews, insects and African squirrels (*Heliosciurus*, and *Funisciurus*). The most significant source of human infection by the mpox virus is likely to be the consumption of animals. The virus has been observed to cause a range of complications in various animal species. For instance, symptoms such as fever, cough, ocular discomfort, poor appetite, and rash have been documented in prairie dogs (*Cynomys ludovicianus*). Additionally, there have been instances where domestic dogs (*Canis familiaris*) have been infected with the virus and exhibited lesions and wounds. It is postulated that small mammals constitute a

reservoir for the virus, particularly in areas where it is endemic (36). The virus is transmitted between animals via fecal-oral transmission or through wounds, the nose, and ingestion of infected meat. The available data on the disease in animals is insufficient, and further studies are currently being conducted (36, 37).

#### 2.7. Transmission

Beginning in 2022, cases of mpox were reported in countries where the disease would not normally occur. To date, African authorities have confirmed 2,863 cases and 517 deaths in 2024, most of them in Congo. Only a small proportion of suspected infections have been genetically tested to confirm the *M. pox* infection and its type, and suspected cases have already exceeded 17,000, surpassing last year's figures of about 15,600 cases and 537 deaths (38). Given the challenges associated with tracking and testing cases, experts hypothesize that the actual number of cases is likely to be significantly higher than the reported figures. The World Health Organization (WHO) has recently designated the outbreak of mpox as a public health emergency (39) (figure 5). The mpox virus can be transmitted via contact with infectious fluids. Such fluids may be present on the skin or genitals, including in instances of touch or close contact. Additionally, the mpox virus may be transmitted from an infected person to another individual through respiratory droplets in the event of prolonged close contact. During the 2022–2023 global outbreak of the type II mpox virus, person-to-person transmission was almost exclusively through sexual contact (40). The risk of contracting this infection through items such as clothes or bedding is less, but in this case, precautions should be taken. The mpox virus is transmitted from person to person in the following ways:

- Direct contact with the rash, scabs or fluids of a person infected with the monkey pox virus
- Prolonged close contact (more than four hours) with the respiratory droplets of an infected person, as well as through sexual contact
- Contact with clothing, sheets, blankets or other items that have been in contact with the rash or body fluids of an infected person
- A pregnant person can transmit the monkey pox virus to the fetus
- Touching the wound or body fluids of a sick person
- Using or touching the patient's personal belongings
- Eating contaminated meat
- Being bitten by a sick animal
- Sexual intercourse and unprotected sex

The mpox virus can be transmitted from animals to humans via direct contact with infected animals, including through skin scratches during activities where humans are in direct contact with infected animals. The virus gains entry through mucosal surfaces (mouth, respiratory tract, and genitals) or broken skin. The mpox virus can be transmitted from animals to humans in the following ways:

- Through bites and scratches by infected animals.



- Through contaminated wild animals that are cooked for food.
- Products such as leather or fur made from infected animals.
- Direct contact with body fluids or skin lesions of animals infected with mpox (41).

The following are more susceptible to mpox and it is necessary for these people to pay special attention to prevention and health care:

1. Face-to-face contact with mpox patients can significantly increase the risk of infection. These people should reduce the risks by observing proper social distance and using personal protective equipment.
2. People who are physically or through sexual contact with infected skin lesions are at high risk. It is necessary for these people to avoid direct contact with other people's wounds and lesions.
3. Contact with clothes or objects infected with the monkey pox virus, even if this contact is 21 days before the onset of symptoms, can have serious consequences. Therefore, people should avoid using clothes or common objects of sick people and if necessary, wash the clothes completely.
4. Traveling to countries where cases of monkey pox infection have been reported is considered a serious risk factor. After returning to their country, these people should pay close attention to the symptoms of the disease and see a doctor if they see any unusual symptoms (42).

### 3. Results

#### 3.1. Diagnosis

Clinical differential diagnosis must consider other rash illnesses, such as chickenpox, measles, bacterial skin infections, scabies, Poison ivy, syphilis and medication-associated allergies. Diagnosis can be verified by testing for the virus. Until now, detection of this virus has been largely limited to testing symptomatic patients with typical lesions. Studies show that the PCR test of skin lesions has the highest sensitivity (clinical sensitivity 91% - 100%) (7, 43, 44). Most of the molecular diagnostic assays for mPox virus are based on real-time quantitative PCR (qPCR) (45, 46). Some rapid antigen and antibody tests have been developed in the format of LFAs for a range of specimen types (serum, plasma, lesions fluid and oropharyngeal swab). To date, both the analytical and clinical performance of these assays are unclear (7). MPox virus culture should be performed in a high containment laboratory (PC3/BSL3) and vaccine is generally recommended for laboratory staff performing this work. mPox virus can be cultured in a number of human (HEK293, HeLa, A549, MRC-5), nonhuman primate (NHP) (Vero, Vero E6, MK2, MA104, RMK), and mammalian (RK13) derived cell lines. Extensive cytopathic effects (CPE) can be observed in as early as 2–3 days post inoculation (47, 48). Serological assessment of mpox infection can be used, for example, identification of self-attenuated infection, assessing population sero prevalence to determine asymptomatic infection, and assessment of population immunity.

However, mpox serology is not extensively utilized in diagnostic laboratories due to lack of commercial assays. There are two major challenges in mpox serological development, limited availability of mPox virus antigens/inactivated viral particles and the second is serological cross-reactivity between *Orthopoxviruses* (49). Despite this, a number of in-house assays (e.g., immunofluorescence assay (IFA), enzyme-linked immunosorbent assay (ELISA), hemagglutination inhibition assay (HAI)) have been developed over the years to meet the demand for surveillance and to differentiate vaccination from natural infection. Notwithstanding the aforementioned limitations, a number of in-house assays (e.g., immunofluorescence assay (IFA), enzyme-linked immunosorbent assay (ELISA), hemagglutination inhibition assay (HAI)) have been developed over the years to meet the demand for surveillance and to differentiate vaccination from natural infection. Given that the utilization of TEM in the differential diagnosis of herpes and smallpox virus infection can be traced back to 1947, during the smallpox outbreak in the United States, direct examination of blister fluid using negative contrast TEM represents a suitable method for the rapid early identification of smallpox virus virions in clinical samples (7).

#### 3.2. Prevention

The control of mpox outbreaks is primarily dependent on the implementation of various public health measures, including proper surveillance, contact tracing, rapid diagnosis, isolation and care of patients, and vaccination (50). In addition to standard precautions, the CDC has provided comprehensive and detailed recommendations for the control of this infection. Among these recommendations are the use of personal protective equipment (PPE) by healthcare workers, including gowns, masks, goggles, and disposable filtering respirators (such as N95), and the isolation of the infected person in a private room to prevent possible contact with others. Individuals residing in countries with a high prevalence of mpox should refrain from contact with dead or live infected mammals, which may serve as reservoirs for the mpox virus. Additionally, they should avoid consuming or coming into contact with wild game. In response to the 2022-2023 outbreak, public health officials initiated public education campaigns with the objective of reducing the spread of the disease. A number of preventative measures can be employed to prevent the transmission of monkeypox. The recommended methods include the following:

- Avoiding direct contact between humans and animals with animals that may carry mpox, such as monkeys and squirrels, etc.
- Avoiding contact with objects in contact with contaminated places with infected animals.
- Avoid contact with sick people with suspected and confirmed mpox.
- Proper disinfection and hand washing after contact with infected objects, places and animals and use of

personal protective equipment when dealing with infected people.

- Thorough washing and proper cooking of animal meat products.
- Isolation of infected people to prevent the spread of infection to other people.
- Use of masks and medical gloves in confirmed mpox cases. Proper disinfection and cleaning of infected places and hospital floors.
- Increase public awareness regarding risks of infection, preventive measures, and possible treatment options.
- People with an increased risk of developing infection such as medical staff, laboratory workers, scientists, response teams, healthcare workers, and captive animals must be subjected to pre-exposure vaccination to avoid infection spread.
- Captive animals with the infection must be separated from other animals with proper quarantine care (51).

Vaccination is the most effective method of preventing infection. However, one of the most effective methods for preventing this disease, as is the case with numerous other viral diseases, is through vaccination and the use of an appropriate vaccine. It is also possible that smallpox vaccines may offer some protection against mpox. In some countries, vaccination is recommended for individuals at risk. It should be noted that not all individuals are eligible for vaccination. The risk of mpox has been demonstrated to be reduced among individuals who have previously received the smallpox vaccine in Africa. A reduction in immunity to smallpox viruses among at-risk populations represents a significant contributing factor to the increased prevalence of human monkeypox. The decline in cross-immunity that occurred after 1980, when mass smallpox vaccination was discontinued, has resulted in an increase in cases of monkeypox disease in humans. As of August 2024, four vaccines are currently in use for the prevention of mpox, although supplies are limited. All were originally developed as a means of combating smallpox.

- MVA-BN (marketed as Jynneos, Imvamune or Imvanex) manufactured by Bavarian Nordic. Licensed for use against mpox in Europe, United States and Canada.
- LC16 from KMB Biologics (Japan) – licensed for use in Japan.
- OrthopoxVac, licensed for use in Russia and manufactured by the State Research Center of Virology and Biotechnology in Russia.
- ACAM2000, manufactured by Emergent Bio Solutions. Approved for use against mpox in the United States as of August 2024.

The MVA-BN vaccine, initially developed for smallpox, has been approved in the United States for individuals deemed at elevated risk of exposure to mpox or who have recently been exposed to it. The United States Centers for Disease Control and Prevention (CDC) recommends that individuals engaged in the investigation of mpox outbreaks, those responsible for the care of infected animals or

individuals, and those who have been exposed to infected individuals or animals through close or intimate contact should receive a vaccination. The primary challenges associated with mpox vaccination pertain to the identification of potential contacts of cases and the subsequent tracing of these individuals within the recommended timeframe (2 weeks) for post-exposure immunization. The restricted accessibility of the available vaccines represents an additional challenge, which can be addressed through the prioritization of vaccination for individuals who are at an elevated risk of the disease (50). The optimal time for individuals to receive the vaccine is prior to exposure to mpox. In the event of exposure to mpox, the administration of a vaccination within four days of the initial exposure offers the greatest probability of disease avoidance. It is probable that vaccination between four and 14 days will result in a reduction in the severity of the disease. Individuals at risk who are planning to travel to a country experiencing a significant outbreak should be vaccinated four to six weeks prior to departure to ensure optimal protection. It is worth noting that both the ACAM2000 and mRNA vaccines have been linked to an uncommon risk of myocarditis (inflammation of the heart muscle) and pericarditis (inflammation of the heart's lining). The risk is highest among young adults, particularly males (53).

### 3.4. Treatment

The objective of treatment for monkeypox is to manage the symptoms of the disease in order to prevent the development of complications. The majority of cases of mpox present with mild symptoms that resolve within a period of 2 to 4 weeks. At present, there is no specific treatment for this disease. However, antiviral drugs, such as tecovirimat, are employed in the treatment of severe mpox. The necessity to rely on supportive drugs and antiviral agents when treatment is required is a consequence of the difficulties encountered in the context of vaccination restrictions. Three drugs are commonly employed in the treatment of mpox: cidofovir, brincidofovir, and tecovirimat (51). To date, no completed randomized controlled trials have been conducted to study the efficacy of therapeutic agents for the treatment of mpox. Additionally, non-randomized controlled trials were identified which evaluated the safety of therapeutics for mpox. It was found that there were no significant risks associated with tecovirimat, and that there was low certainty evidence suggesting that brincidofovir may cause mild liver injury (54). Pain is a common and potentially severe symptom. Therefore, supportive care, such as the administration of analgesics or antipyretics, may be provided. Individuals with mild disease should remain isolated at home, maintain adequate hydration, adhere to a nutritious diet, and take measures to preserve their mental well-being. Those at elevated risk for the disease include children, pregnant women, the elderly, and those with immunocompromising conditions. For patients exhibiting severe symptoms or at high risk for complications,

hospitalization and close observation are advised. It is recommended that symptomatic treatment be employed for complications such as proctitis and pruritis. A trial conducted in the Democratic Republic of the Congo revealed that the antiviral drug tecovirimat did not result in a reduction in the duration of mpox lesions in patients with clade I mpox. Notwithstanding, the trial's overall mortality rate of 1.7% was markedly lower than the 3.6% or higher mortality rate observed in the Democratic Republic of the Congo's general mpox cases. These findings indicate that hospitalization and high-quality supportive care are associated with improved outcomes for patients with mpox. The trial was sponsored by the National Institutes of Health (NIH) and co-led by the Democratic Republic of the Congo's Institut National de Recherche Biomédicale (55). The drug was licensed in 2018 for the treatment of vaccinia virus infections. It serves as an alternative to antiviral agents. Derivatives of this approach, namely recombinant immunoglobulins (rVIG), are currently under investigation and represent a strategic passive immunotherapy (56-58).

#### 4. Conclusion

The World Health Organization (WHO) has identified a public health emergency in response to the recent outbreak of monkeypox in several regions of the African continent. These concerns are particularly attributable to the proliferation of a novel viral strain, which researchers have identified as being more virulent than previous variants of the same virus (59). As indicated by the WHO, the threat of mpox is significant on a global scale and has also manifested in other non-African countries. The organization further stated that, despite the relatively high prevalence of the disease in a short period of time, it is unlikely to become a global epidemic, as has been the case with the Coronavirus. Additionally, the virus is transmitted via direct contact or contact with infected secretions, which limits its contagiousness and reduces the likelihood of an epidemic (60). The current outbreak of mpox is of greater concern than previous outbreaks. Given the considerable volume of travel to and from the African continent, the potential for the new strain to spread among different populations and reach other parts of the world is a significant concern. This has the potential to develop into a global crisis. In light of the current situation, the World Health Organization (WHO) has issued a recommendation that individuals presenting symptoms of mpox should refrain from direct contact with others until all lesions have fully healed. Furthermore, in the event of exposure to an infected surface or individual, it is imperative to adhere to the recommended protocol of handwashing with soap and water to minimize the risk of virus transmission (61). The definitive identification of the natural reservoir of the mpox virus has yet to be determined. It is hypothesized that small rodents may serve as the primary reservoir for this virus. In the absence of a comprehensive vaccination program, the incidence of mpox in humans would persist indefinitely in endemic regions, with the potential for the disease to spread

to non-endemic areas. Further evidence suggests that the virus is evolving to become more transmissible between humans and to infect a wider range of host species, and that human-to-animal transmission may also occur. It is therefore possible that an epidemic state of the disease may occur in the future. In light of the 2024 WHO designation of the monkeypox virus as a "priority pathogen" with pandemic potential, the likelihood of an epidemic of the disease on a global scale cannot be discounted (62). In light of the ongoing Coronavirus disease (Covid-19) pandemic, the possibility of a subsequent outbreak of monkeypox cannot be discounted. It is therefore imperative that healthcare professionals in all countries are fully informed about the virus and the disease it causes, as well as the means of preventing infection, with vaccination being a particularly important method of protection.

#### Acknowledgment

We would like to thank all of our colleagues in Razi vaccine & serum research institute for kind cooperation.

#### Authors' Contribution

Study concept and design: S. S

Acquisition of data: S.S

Analysis and interpretation of data: S.S., N. M

Drafting of the manuscript: S.S., N. M

Critical revision of the manuscript for important intellectual content: S. S

Statistical analysis: S.S

Administrative, technical, and material support: S.S., N. M.

#### Ethics

We hereby declare all ethical standards have been respected in preparation of the submitted article.

#### Conflict of Interest

The authors declare that they have no conflict of interest.

#### Grant Support

The authors confirm that they did not receive any financial assistance for the research, authorship, and/or publication of this article

#### Data Availability

The data that support the findings of this study are available on request from the corresponding author.

#### References

- Mitjà O, Ogoina D, Titanji BK, Galvan C, Muyembe J-J, Marks M, et al. Monkeypox. *The Lancet*. 2023;401(10370):60-74.
- Letafati A, Sakhavarz T. Monkeypox virus: A review. *Microbial pathogenesis*. 2023;176:106027.

3. Parker S, Buller RM. A Review of Experimental and Natural Infections of Animals with Monkeypox Virus Between 1958 and 2012. *Future Virology*. 2013;8(2):129-57.
4. Adepoju P. Mpox declared a public health emergency. *The Lancet*. 2024;404(10454):e1-e2.
5. Karagoz A, Tombuloglu H, Alsaeed M, Tombuloglu G, AlRubaihi AA, Mahmoud A, et al. Monkeypox (mpox) virus: Classification, origin, transmission, genome organization, antiviral drugs, and molecular diagnosis. *Journal of Infection and Public Health*. 2023;16(4):531-41.
6. Cho CT, Wenner HA. Monkeypox virus. *Bacteriological reviews*. 1973;37(1):1-18.
7. Lim CK, Roberts J, Moso M, Liew KC, Taouk ML, Williams E, et al. Mpox diagnostics: Review of current and emerging technologies. 2023;95(1):e28429.
8. Okwor T, Mbala PK, Evans DH, Kindrachuk J. A contemporary review of clade-specific virological differences in monkeypox viruses. *Clinical Microbiology and Infection*. 2023;29(12):1502-7.
9. Yu X, Shi H, Cheng G. Mpox Virus: Its Molecular Evolution and Potential Impact on Viral Epidemiology. 2023;15(4):995.
10. Li Y, Lv S, Zeng Y, Chen Z, Xia F, Zhang H, et al. Evaluation of Stability, Inactivation, and Disinfection Effectiveness of Mpox Virus. 2024;16(1):104.
11. Lansiaux E, Jain N, Laivacuma S, Reinis A. The virology of human monkeypox virus (hMPXV): A brief overview. *Virus Res*. 2022;322:198932.
12. Basu K, Krugliak M, Arkin IT. Viroporins of Mpox Virus. 2023;24(18):13828.
13. Gessain A, Nakoune E, Yazdanpanah Y. Monkeypox. *The New England journal of medicine*. 2022;387(19):1783-93.
14. Ogoina D, Dalhat MM, Denué BA, Okowa M, Chika-Igwenyi NM, Yusuff HA, et al. Clinical characteristics and predictors of human mpox outcome during the 2022 outbreak in Nigeria: a cohort study. 2023;23(12):1418-28.
15. Americo JL, Earl PL, Moss B. Virulence differences of mpox (monkeypox) virus clades I, IIa, and IIb.1 in a small animal model. 2023;120(8):e2220415120.
16. Branda F, Romano C, Ciccozzi M, Giovanetti M, Scarpa F, Ciccozzi A, et al. Mpox: An Overview of Pathogenesis, Diagnosis, and Public Health Implications. 2024;13(8):2234.
17. Ogoina D, Damon I, Nakoune E. Clinical review of human mpox. *Clinical Microbiology and Infection*. 2023;29(12):1493-501.
18. Adetifa I, Muyembe J-J, Bausch DG, Heymann DL. Mpox neglect and the smallpox niche: a problem for Africa, a problem for the world. *The Lancet*. 2023;401(10390):1822-4.
19. Mortier C, Tissot-Dupont H, Cardona F, Bruel C, Lahouel S, Lasri H, et al. How to distinguish mpox from its mimickers: An observational retrospective cohort study. 2023;95(10):e29147.
20. McCollum AM, Damon IK. *Clinical Infectious Diseases*. 2014;58(2):260-7.
21. Christodoulidou MM, Mabbott NA. Efficacy of smallpox vaccines against Mpox infections in humans. *Immunotherapy advances*. 2023;3(1):ltad020.
22. León-Figueroa DA, Barboza JJ, Garcia-Vasquez EA, Bonilla-Aldana DK, Diaz-Torres M, Saldaña-Cumpa HM, et al. Epidemiological situation of monkeypox transmission by possible sexual contact: a systematic review. 2022;7(10):267.
23. Bunge EM, Hoet B, Chen L, Lienert F, Weidenthaler H, Baer LR, et al. The changing epidemiology of human monkeypox-A potential threat? A systematic review. *PLoS Negl Trop Dis*. 2022;16(2):e0010141.
24. YAO Kai-Hu DQ-Q, HU Ya-Hong. Diagnosis and treatment of human monkeypox. 2022;24(9):960-6.
25. Caldas JP, Valdoleiros SR, Rebelo S, Tavares M. Monkeypox after Occupational Needlestick Injury from Pustule. *Emerg Infect Dis*. 2022;28(12):2516-9.
26. McFarland SE, Marcus U, Hemmers L, Miura F, Iñigo Martínez J, Martínez FM, et al. Estimated incubation period distributions of mpox using cases from two international European festivals and outbreaks in a club in Berlin, May to June 2022. *Euro surveillance : bulletin European sur les maladies transmissibles = European communicable disease bulletin*. 2023;28(27).
27. Estévez S, Vara M, Gamo M, Manzano S, Troya J, Botezat E, et al. Epidemiological and Clinical Characteristics of Patients Admitted to a Secondary Hospital with Suspected MPOX Virus Infection: Is HIV Playing a Role? *Journal of clinical medicine*. 2023;12(12).
28. McCollum AM. *MMWR*. 2023;72.
29. Blackburn DJ. *MMWR*. 2022;71.
30. Ferdous J, Berek MA, Hossen MS, Bhowmik KK, Islam MS. A review on monkeypox virus outbreak: New challenge for world. *Health science reports*. 2023;6(1):e1007.
31. Shoaib HM. *JFIPH*. 2023;11:1254545.
32. Siddiqui A, Essar MY, Rija A, Head MG, Nemat AJ. *JoS*. Improving health system access and preparedness in Afghanistan to minimize potential impact of monkeypox: a call for action. 2023;109(2):156-7.
33. Coşkun E, Soyak F, Öztürk-Deniz SS, Kutlu M, Sayın-Kutlu SJ. *JID, Microbiology C*. Four Human Mpox Cases from Turkey. 2023;5(1):53.
34. Ahmed SK, Abdulqadir SO, Omar RM, Abdullah AJ, Rahman HA, Hussein SH, et al. Knowledge, Attitude and Worry in the Kurdistan Region of Iraq during the Mpox (Monkeypox) Outbreak in 2022: An Online Cross-Sectional Study. *Vaccines (Basel)*. 2023;11(3).
35. Grothe JH, Cornely OA, Salmanton-García JJEIyMC. Monkeypox in children and adult women in Europe: Results from a flash VACCELERATE pilot survey. 2023;41(5):309.
36. Dumonteil E, Herrera C, Sabino-Santos G. Monkeypox Virus Evolution before 2022 Outbreak. *Emerg Infect Dis*. 2023;29(2):451-3.

37. Faherty EAJMM, Report MW. Notes from the field: emergence of an mpox cluster primarily affecting persons previously vaccinated against mpox—Chicago, Illinois, March 18–June 12, 2023. 2023;72.
38. Meyer H, Perrichot M, Stemmler M, Emmerich P, Schmitz H, Varaine F, et al. Outbreaks of Disease Suspected of Being Due to Human Monkeypox Virus Infection in the Democratic Republic of Congo in 2001. *Journal of Clinical Microbiology*. 2002;40(8):2919-21.
39. Srivastava S, Kumar S, Jain S, Mohanty A, Thapa N, Poudel P, et al. The Global Monkeypox (Mpox) Outbreak: A Comprehensive Review. *Vaccines (Basel)*, 2023;11(6).
40. Gaeta F, De Caro F, Franci G, Pagliano P, Vajro P, Mandato CJC. Monkeypox Infection 2022: An Updated Narrative Review Focusing on the Neonatal and Pediatric Population. 2022;9(12):1832.
41. Seang S, Burrell S, Todesco E, Leducq V, Monsel G, Le Pluart D, et al. Evidence of human-to-dog transmission of monkeypox virus. *Lancet*. 2022;400(10353):658-9.
42. Besombes C, Mbrengra F, Malaka C, Gonofio E, Schaeffer L, Konamna X, et al. Investigation of a mpox outbreak in Central African Republic, 2021–2022. 2023;16:100523.
43. Thornhill JP, Barkati S, Walmsley S, Rockstroh J, Antinori A, Harrison LB, et al. Monkeypox Virus Infection in Humans across 16 Countries — April–June 2022. 2022;387(8):679-91.
44. Adler H, Gould S, Hine P, Snell LB, Wong W, Houlihan CF, et al. Clinical features and management of human monkeypox: a retrospective observational study in the UK. *The Lancet Infectious Diseases*. 2022;22(8):1153-62.
45. Iizuka I, Saijo M, Shiota T, Ami Y, Suzaki Y, Nagata N, et al. Loop-mediated isothermal amplification-based diagnostic assay for monkeypox virus infections. 2009;81(6):1102-8.
46. Davi SD, Kissenkötter J, Faye M, Böhlken-Fascher S, Stahl-Hennig C, Faye O, et al. Recombinase polymerase amplification assay for rapid detection of Monkeypox virus. *Diagnostic Microbiology and Infectious Disease*. 2019;95(1):41-5.
47. Gong Q, Wang C, Chuai X, Chiu S. Monkeypox virus: a re-emergent threat to humans. *Virologica Sinica*. 2022;37(4):477-82.
48. Cho CT, Wenner HAJPotSfEB, Medicine. In vitro growth characteristics of monkeypox virus. 1972;139(3):916-20.
49. Esposito JJ, Obijeski JF, Nakano JH. Serological relatedness of monkeypox, variola, and vaccinia viruses. 1977;1(1):35-47.
50. Rana J, Patel SK, Agrawal A, Channabasappa NK, Niranjan AK, Chandra Das B, et al. Mpox vaccination in global perspective: priorities and challenges. *Annals of Medicine and Surgery*. 2023;85(5).
51. Malik S, Ahmad T, Ahsan O, Muhammad K, Waheed Y. Recent Developments in Mpox Prevention and Treatment Options. 2023;11(3):500.
52. Wolff Sagy Y, Zucker R, Hammerman A, Markovits H, Ariei NG, Abu Ahmad W, et al. Real-world effectiveness of a single dose of mpox vaccine in males. *Nature Medicine*. 2023;29(3):748-52.
53. Berry MT, Khan SR, Schlub TE, Notaras A, Kunasekaran M, Grulich AE, et al. Predicting vaccine effectiveness for mpox. *Nature Communications*. 2024;15(1):3856.
54. Group CID, Fox T, Gould S, Princy N, Rowland T, Lutje V, et al. Therapeutics for treating mpox in humans. 1996;2023(3).
55. Siegrist EA, Sassine JJCid. Antivirals with activity against mpox: a clinically oriented review. 2023;76(1):155-64.
56. Kumar N, Acharya A, Gendelman HE, Byrareddy SNJJoA. The 2022 outbreak and the pathobiology of the monkeypox virus. 2022;131:102855.
57. Turner M, Mandia J, Keltner C, Haynes R, Faestel P, Mease LJEID. Monkeypox in patient immunized with ACAM2000 smallpox vaccine during 2022 outbreak. 2022;28(11):2336.
58. Kozlov M. Can a Smallpox Drug Treat Monkeypox? What Scientists Know. *NATURE PORTFOLIO HEIDELBERGER PLATZ 3, BERLIN, 14197, GERMANY*; 2022.
59. Beer EM, Rao VBJPntd. A systematic review of the epidemiology of human monkeypox outbreaks and implications for outbreak strategy. 2019;13(10):e0007791.
60. Falendysz EA, Lopera JG, Lorenzsonn F, Salzer JS, Hutson CL, Doty J, et al. Further assessment of monkeypox virus infection in Gambian pouched rats (*Cricetomys gambianus*) using in vivo bioluminescent imaging. 2015;9(10):e0004130.
61. Sklenovská N, Van Ranst M. Emergence of Monkeypox as the Most Important Orthopoxvirus Infection in Humans. *Frontiers in public health*. 2018;6:241.
62. Nguyen P-Y, Ajisejiri WS, Costantino V, Chughtai AA, MacIntyre CRJEID. Reemergence of human monkeypox and declining population immunity in the context of urbanization, Nigeria, 2017–2020. 2021;27(4):1007.