

Original Article

Anti-inflammatory Effect of Aqueous Extract of *Cassia fistula* in Acetic Acid Model of Colitis in Rats

Mohsen Zabihi¹, Anoosheh Ahmadi² and Raheleh Zareshahi*^{3,4}

¹ Department of Pharmacology, School of Pharmacy, Shahid Sadoughi University of Medical Sciences, Yazd, Iran

² Department of Pharmacology, School of Pharmacy, Shahid Sadoughi University of Medical Sciences, Yazd, Iran

³ Department of Pharmacognosy, School of Pharmacy, Shahid Sadoughi University of Medical Sciences, Yazd, Iran

⁴ Herbal Medicines Research Center, School of Pharmacy, Shahid Sadoughi University of Medical Science Health Services, Yazd, Iran

Article History

Received: 11 October 2023
Accepted: 28 December 2023
© 2012 Iranian Society of Medicinal Plants.
All rights reserved.

Keywords

Ulcerative colitis
Cassia fistula
Rats
MPO
Inflammation

*Corresponding author

rahele.zareshahi@gmail.com

ABSTRACT

Considering the beneficial effects of herbal medicine in comparison with synthetic drugs and also the recommendation of Iranian medical scholars on the use of *Cassia fistula* L. in gastrointestinal inflammations, in this study the effect of aqueous extract of *C. fistula* fruit on the histopathological improvement of ulcerative colitis was evaluated in rats. In this study, 30 rats with a weight range of 250-300 g and about 2 months were used. Ulcerative colitis was induced by acetic acid in rats, then the animals were treated orally with normal saline, sulfasalazine (360 mg/kg), or aqueous extract of *C. fistula* (600 and 800 mg/kg) once daily for 5 days. The animals were then sacrificed and their colons were evaluated macroscopically, histopathologically, and for myeloperoxidase (MPO) activity and weight. The severity and extent of colonic inflammation in animals receiving 400 and 800 mg/ml of *C. fistula* extract showed a significant decrease compared to those receiving normal saline ($P < 0.05$). A decrease in colon weight was observed in the group of animals receiving a concentration of 800 mg/ml of the extract. *C. fistula* aqueous extract did not show any effect in reducing the activity of the MPO enzyme.

INTRODUCTION

Inflammatory bowel disease is one of the most common diseases of the gastrointestinal tract. Current demographic studies have estimated the prevalence of this disease to be approximately one patient per two hundred population in European countries [1]. Currently, the best treatment for this disease is the use of anti-inflammatory drugs such as corticosteroids and aminosalicylates, but these drugs have severe side effects [2], so extensive studies are conducted to use natural remedies, especially anti-inflammatory drugs. Oxidants should be used to control these diseases [3]. Ulcerative colitis is one of the inflammatory bowel diseases that was first introduced in 1909 in England [4]. The disease affects the colon and its symptoms include dysentery, nausea, bloating, nocturnal diarrhea, and bleeding from the rectum [5, 6]. Although the exact cause of this disease is not yet known, several factors such as viral infection, food allergies, contraceptives, appendectomy, and tonsillectomy, as well as cultural, genetic, and

geographical factors, are involved in its development [7]. Cassia-pulp (*Cassia fistula*) is recommended in traditional Iranian medicine as one of the effective plants in the treatment of inflammatory bowel disease (IBD). The organs of *C. fistula* are known as a rich source of secondary metabolites, especially phenolic compounds, which have wound healing and anti-inflammatory effects. The aqueous extract of its root has anti-inflammatory effects [8]. This study aimed to evaluate the effect of *C. fistula* aqueous extract in the treatment of acetic acid-induced colitis in rats, considering the pharmacological effects of *C. fistula* and the need for safer and more effective treatments for IBD.

MATERIALS AND METHODS

Preparing of Extract

The fruit of *C. fistula* was purchased from Yazd Medicinal Plants Market and was approved by the herbalist and, maintained in the herbarium of the Department of pharmacognosy of Yazd School of

Pharmacy with voucher number SSU0056. The inner pulps of the fruit were separated and after grinding and pulverizing, 50 g of it was mixed with distilled water and boiled for 30 minutes, and finally, it was filtered through filter paper and dried at laboratory temperature (extraction).

Total Phenol Content

To measure total phenolic compounds, seven concentrations of standard gallic acid solution (10-200 µg/ml) were prepared. Then 0.5 ml of 10% folin ciocalteu solution was added to 0.1 ml of the resulting solution and after 3-8 minutes 0.4 ml of 7.5% sodium carbonate was added and kept for 30 minutes at laboratory temperature and then 300 µl of each sample was poured into microplate wells and the UV absorption was measured at 760 nm. The mean absorbance of the samples was plotted and total phenol was measured.

Secondary Metabolites Identification

Tests to identify alkaloids, anthraquinones, tannins, and saponins were performed as follows [9].

A. Alkaloid Identification

The plant powder (0.5 g) was distilled with 1 ml HCl 2 N and 9 ml of distilled water and placed on Ben-Marie for 5 minutes after cooling the resulting solution and poured into the clock glass and added two reagents of Iodine and Dragendorf and the resulting sediment indicates the presence of alkaloid.

B. Anthraquinone Identification (Borntraeger)

The plant powder (0.2 g) in 5 ml sulfuric acid (2 N) was heated by Ben-Marie for 5 minutes. Then the extract was decanted by 10 ml toluene and separated the toluene phase then the toluene phase was decanted by NaOH 2 N, the red-blue phase, which indicates the presence of anthraquinones.

C. Tannin Identification

The plant powder (2 g) was mixed with 10 ml ethanol for 5 minutes and after filtering, added a few drops of FeCl₃, which in the case of green color indicates the presence of tannin.

D. Saponin Identification

0.1 g of the plant powder (0.1 g) was poured into the balloons and added 10 ml of boiling water to it after cooling 30 seconds combined 10 minutes, creating foam, then added 3 drops of HCl 2N, if the foam was stable, it indicates there is saponin in the extract.

Animals

In keeping and working with animals, the principles of working with laboratory animals of the ethics committee of Shahid Sadoughi University of Medical Sciences of Yazd with the ID IR.SSU.MEDICINE.REC.1397.232 were considered. Thirty rats weighing 250-300 grams were purchased from the animal house of Shahid Sadoughi University of Medical Sciences in Yazd and the animals were kept in special cages with suitable light, humidity, and temperature conditions (50-60%, 20-23 °C). In none of the groups did the rats die until the end of the study.

Induction of Ulcerative Colitis

The animals were fasted for 24 hours with free access to water and subsequently anesthetized by intraperitoneal injection of ketamine hydrochloride (50 mg/kg) (Alfasan, Netherlands) and xylazine (10 mg/kg) (Alfasan, Netherlands). After complete anesthesia, an 8 cm long feeding tube was placed in the animal's rectum and 2 mL of 4% acetic acid was inoculated intrarectally, then animals were hung upside down for 30 seconds, and then the colon was washed with 1 ml of normal saline [10].

Experimental Design

The animals were randomly divided into five groups, including sham group, induction of colitis with normal saline instead of acetic acid and treatment with normal saline; Control group, induction of colitis with acetic acid and treatment with normal saline; Standard group, induction of colitis with acetic acid and treatment with sulfasalazine (360 mg/kg); *C. fistula* extract groups, induction of colitis with acetic acid and treatment with aqueous *C. fistula* extract at a concentration of 400 or 800 mg/kg body weight. The oral treatments were used for all groups.

During the study, all rats were weighed and after 5 consecutive days of treatment, the animals were sacrificed and 8 cm of their colon was cut after the rectum and after making a longitudinal incision was washed with normal saline. The colon weight, macroscopic score, and histopathology, as well as colonic tissue MPO activity, were evaluated.

Colon Weight Assessment

The cut colon (8 cm) was weighed by scales after washing and drying, and the weight-to-length ratio of the colon was calculated.

Macroscopic Evaluation of the Colon

The isolated colon was photographed and the lesions were scored using Fiji software.

Five scores were determined for the severity of the lesions, including 0, without any macroscopic changes in the appearance of the colon; 1, erythema observation; 2, mild edema or bleeding or destruction of mucosal tissue; 3, moderate conditions of edema and destruction of mucosal tissue; 4: severe edema or ulceration and destruction of mucosal tissue; 5, mucosal tissue necrosis. By substituting the overall level of inflammation and score, the severity of the lesions was calculated in the formula below the ulcer [11, 12]. Ulcer index = Ulcer area (cm²) + Macroscopic score.

Histopathological Evaluation of the Colon

Table 1 Histopathologic score

Appearance	Score
Normal	0
Localized hyperemia, without ulcers	1
Linear wound without significant inflammation	2
Linear wound with inflammation at one point	3
Two or more wounds with or without inflammation	4
Two or more points of inflammation and wound or a large area of inflammation and wound more than one centimeter long along the colon	5

Measurement of Myeloperoxidase (MPO) activity

Part of the colon was removed, weighed, and kept at minus 70 ° C. The samples were then homogenized separately in 10 mM potassium phosphate buffer with pH=7 containing 0.5% hexadecyl trimethyl ammonium bromide. The samples were then centrifuged at 20000 g for 30 minutes at 4 °C and H₂O₂ (0.1 mM) and tetramethyl benzidine (1.6 mM) were added to the supernatant of the centrifuged tubes and the sample absorbance was measured at 450 nm. MPO activity was calculated and reported as pg/mg of colon tissue [13].

Data Analysis

One-way ANOVA statistical analysis followed by Tukey post-hack was used to evaluate the parametric data and the Mann-Whitney test was used to evaluate the non-parametric data. Also, according to the measured parameters, we selected the desired statistical index (Mean ± SEM) or Medium (range). Graphs were determined using Excel 2013 program and final data processing was determined using SPSS 16.

A sample of 20 mm was prepared from the colon tissue and immediately fixed in 10% formalin. In the tissue processor, different stages of dehydration, and clarification by xylene and paraffin were performed. Sections 5-6 microns thick were prepared from the tissue and then the sample was placed in water and alcohol to remove wrinkles. The samples were then taken from water with a slide impregnated with glycerin albumin adhesive and stained with hematoxylin and eosin.

Some disease indicators such as severity and degree of inflammation, degree of inflammation, and percentage of the affected area were examined by light microscope, and the histopathological score in each sample was calculated according to table 1.

RESULTS

Total Phenol Content

The result of the standardization of total flavonoid compounds was calculated based on the folin Ciocalte method at 760 nm wavelength equal to 10.45 µg/ml. The results of the evaluation of secondary metabolites showed the presence of alkaloids, saponins, and anthraquinones. The tannin test was negative.

Effect of *C. fistula* on Colon Weight

Induction of ulcerative colitis in rats was associated with increased colon weight of animals in the control group compared with the sham group (P< 0.05). Treatment of the animals with ulcerative colitis with *C. fistula* at a dose of 800 mg/kg caused a decrease in the colon weight of animals compared to the control group (P< 0.05) (Fig. 1).

Results of Macroscopic Evaluation of colon Damage

Induction of ulcerative colitis in rats was associated with increased levels of inflammation, ulceration, thickening of the colon epithelium, edema, and sometimes colon necrosis in control animals

compared with the sham group. Treatment of animals with ulcerative colitis with sulfasalazine at a dose of 360 mg/kg showed a decreasing effect on the level of inflammation in comparison with the control group ($P < 0.05$) (Fig. 2).

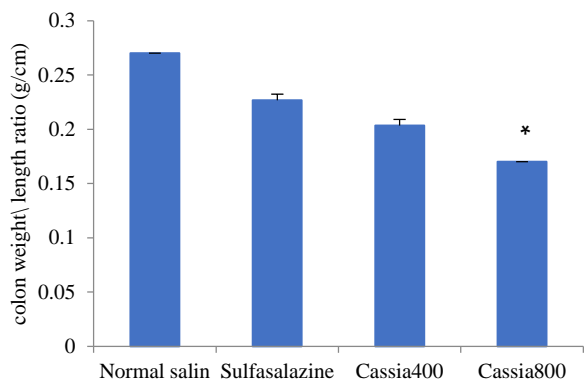


Fig. 1 Changes in the ratio of colon weight to colon length in the experimental groups; Cassia 400 and 800: *C. fistula* extracts of 400 and 800 mg/ml respectively; *, Significant difference ($P < 0.05$) compared to the control group (normal saline).

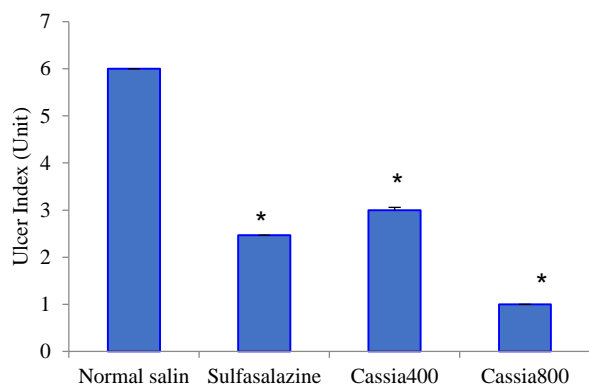


Fig. 2 Comparison of the average macroscopic score of different concentrations of aqueous extract of *C. fistula* with control groups (normal saline); Cassia 400 and 800, *C. fistula* extracts of 400 and 800 mg/ml respectively; *, Significant difference ($P < 0.05$) compared to the control group. The results were calculated using the Fiji program and using the following equation; Ulcer index = Ulcer area (cm^2) + Macroscopic score.

Histopathological Results of Colon Tissue

Tissue changes in the structure of the colon wall, which includes mucosal, submucosal, muscular, and serous layers, respectively, were examined. In the sham group, the normal structure of the colon is seen with 4 separate layers (Fig. 4). In the control group, hematoxylin and eosin-stained incisions show severe changes in colonic tissue without clear demarcation of the layers.

Necrosis and ulceration in all layers of the colon with hemorrhage and formation of fibrin streaks are quite evident in the control group (Fig. 5). Hematoxylin and eosin-stained incisions show severe changes in colonic tissue without clear demarcation of the layers in the control group.

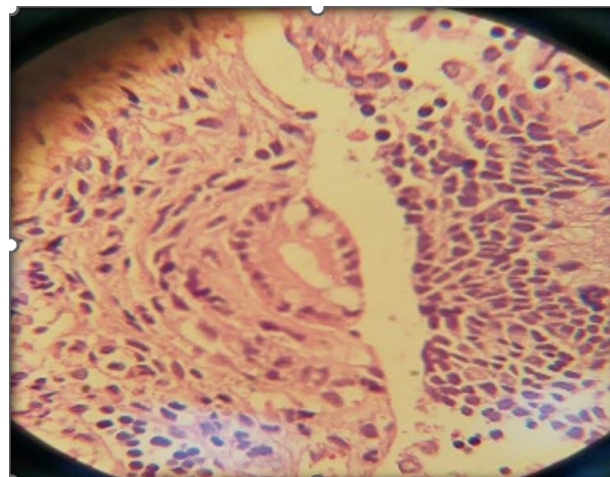


Fig. 3 Microscopic image of the pathological section of the sham group (by hematoxylin-eosin staining, magnification 100) shows the tissue changes in the structure of the colon wall, which include mucosal, submucosal, muscular, and serous layers, respectively, from inside to outside. The normal structure of the colon can be seen with 4 separate layers

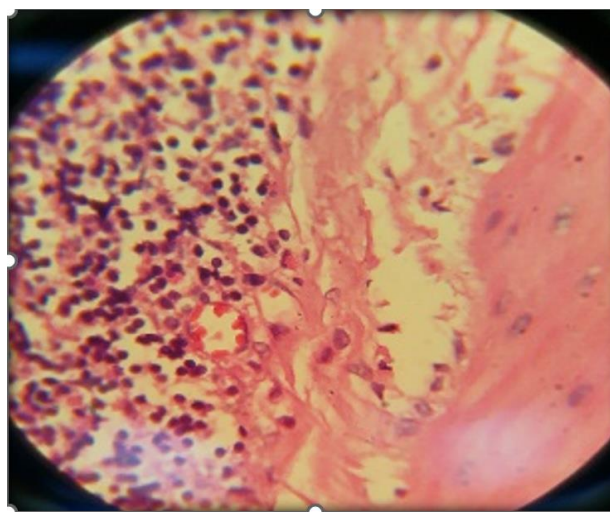


Fig. 4 Microscopic image of the pathology group of the control group with hematoxylin-eosin staining method, magnification 100, the severity of the damage is observed at maximum. Bleeding wounds in all layers, with a large extent, and with tissue necrosis, abundant inflammation is observed in this group. The severity of inflammation indicates the infiltration of inflammatory cells and the degree of severity indicates the involvement (Inflammation Extent) of inflammation in different parts of the wall width, including mucosa, submucosa, or across the width of the colon wall, which indicates necrosis along the cell membrane. With hemorrhage and the formation of fibrin

filaments, a large infiltration of inflammatory cells and significant edema in the submucosal layers are observed.

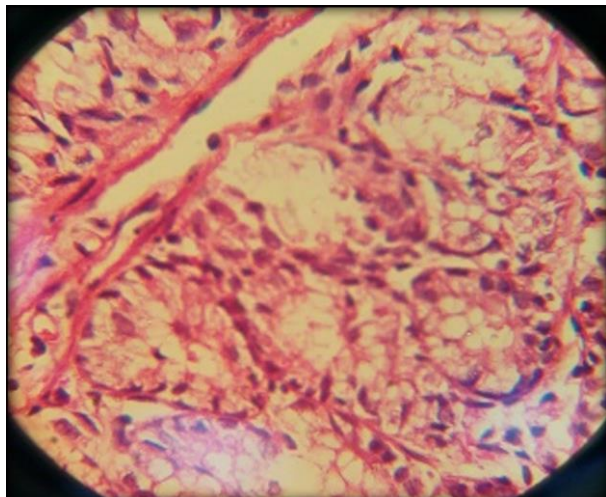


Fig. 5 Microscopic image of the pathological section of the sulfasalazine group by hematoxylin-eosin staining method, magnification 100. Shows the reduction of bleeding and inflammation, the rupture caused by the induction of colitis by acetic acid, in the marked parts point bleeding, the reduction of edema is observed in the submucosal layer.

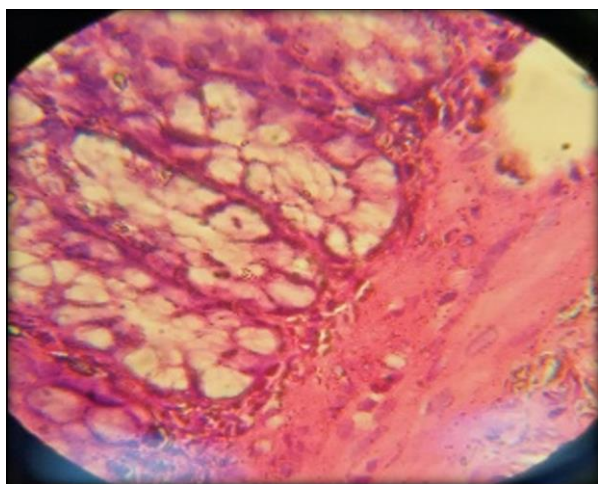


Fig. 6 Microscopic image of the pathological section of the 400 mg extract group by hematoxylin-eosin staining method, magnification 100, the group receiving the dose of 400 mg/kg *C. fistula* extract in comparison with the control group, shows a favorable condition in terms of tissue changes. The lesions in this group are focal while other parts of the colon are seen as normal. Infiltration of inflammatory cells was also seen in the lower part of the affected area.

Necrosis and ulceration in all colonic layers are accompanied by bleeding and formation. These abnormal histopathological signs and symptoms are significantly differentiated compared to the treatment groups receiving doses of 400 mg/ml and 800 mg/ml *C. fistula* extract (Fig. 5). The microscopic image of the pathological section of the sulfasalazine group shows a reduction in bleeding and inflammation, and

in the marked areas, spot bleeding and a decrease in edema in the submucosal layer are observed (Fig. 6). The group receiving the dose of 400 mg/kg of *C. fistula* extract, compared to the control group, showed a favorable condition in terms of tissue changes, so that the wounds in this group are focal, while other parts of the colon are normal. It seems. Infiltration of inflammatory cells was also seen in the lower part of the affected area (Fig. 7). In the 800 mg/kg *C. fistula* group, all of these symptoms improved compared to the control group, and microscopic sections showed only a small wound, while the rest of the mucosa was repaired (Fig. 3-7).

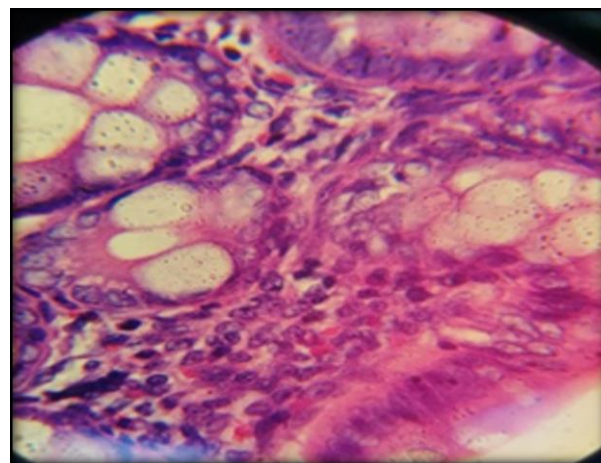


Fig. 7 Microscopic image of the pathological section of the 800 mg extract group by hematoxylin-eosin staining method, magnification 100, the treatment group receiving the dose of 800 mg/kg *C. fistula* compared to the control group showed improvement of all the mentioned symptoms. Microscopically, they show only a small wound, while the rest of the mucosa has healed.

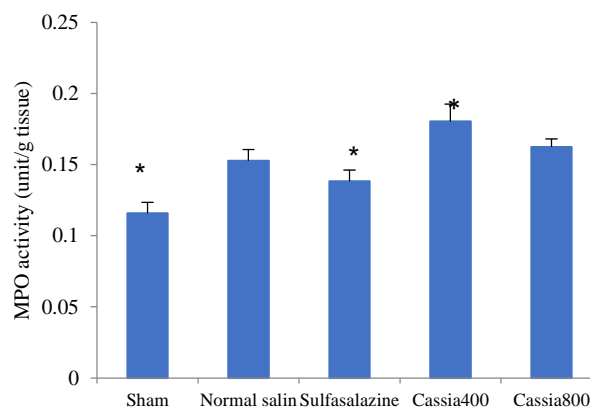


Fig. 8 Mean MPO enzyme activity in different groups. Cassia 400 and 800, *C. fistula* extracts of 400 and 800 mg/ml respectively; *, Significant difference compared to the control group (normal saline) ($P < 0.05$)

Changes in MPO Enzyme Activity

MPO activity of colon tissue with 400 mg *C. fistula* extract was significantly higher than the normal saline

group ($P < 0.05$) but this difference between Cassia 800 and normal saline was not significant ($P > 0.05$) (Fig. 8)

DISCUSSION

The results of this study showed that aqueous extract of *C. fistula* at doses of 400 and 800 mg/kg can improve macroscopic and histopathological criteria in the rat colitis model but has no effect on MPO activity and even increase the enzyme. The activity of a dose of 800 mg/kg aqueous extract of *C. fistula* significantly reduced the weight of the colon after colitis induction compared to the control group ($P < 0.05$). Also, the difference between this group and the sulfasalazine group was not significant ($P > 0.05$). The difference between the macroscopic scores was significant between all of the groups. Doses of 400 and 800 mg/kg reduced the macroscopic score, but doses of 800 mg/kg reduced this score more than other groups ($P < 0.05$). Histopathological findings of the 800 mg/kg group were significantly different from the control group ($P < 0.05$). Colitis is caused by an abnormal immune response to luminal antigens. This tissue damage leads to the release of inflammatory mediators, including acidic metabolites and inflammatory cytokines. In particular, increased secretion of proinflammatory cytokines plays an important role in exacerbating IBD, and many clinical studies have targeted these inflammatory cytokines such as IL-6 (Interleukin-6), and TNF- α (Tumor Necrosis Factors- α). In particular, increased secretion of proinflammatory cytokines such as IL-6 and TNF α appears to play an important role in exacerbating IBD [14].

Histopathological examination in this study showed that the severity of inflammation, the extent of the affected area, and changes in the weight-to-length ratio in pathological observations in the group that received the highest dose of *C. fistula* extract 800 mg/kg had a significant decrease compared to the sham group ($P < 0.05$). Also, the mean severity of inflammation in the treated groups with all water concentrations showed a significant difference from the mean severity of inflammation in the control group ($P < 0.05$). Intracranial degradation due to acetic acid in this animal model of colitis leads to the destruction of the mucosal barrier, colon structure, and inflammatory cell infiltration [15]. The results of this study show that *C. fistula* extract reduces inflammation caused by acetic acid. It is noteworthy that inflammation spreads at three levels, the first

level involving increased vascular permeability that causes protein-rich fluid to drain from the bloodstream into the interstitial tissue, the second level involving leukocyte infiltration from the bloodstream into the interstitial tissue, and the third level it involves the formation of granulomas and tissue repair, and since aqueous Cassia– pulp extract can reduce the severity of inflammation, it seems that aqueous Cassia– pulp extract can reduce vascular permeability in the inflammatory process. The results of the present study showed that two concentrations of 400 and 800 mg/kg aqueous extract of *C. fistula* did not affect reducing MPO activity in the colitis model in rats. MPO activity is a hallmark of gastrointestinal inflammation and oxidative stress that is widely used in laboratory IBD models to examine the pathophysiology of disease as well as the effectiveness of therapeutic interventions [15]. Measuring MPO activity is the second level of inflammation assessment. Therefore, based on the results of this study, an aqueous extract of *C. fistula* can not reduce the infiltration of polymorphonuclear leukocytes [15]. Cassia–pulp is rich in phenolic antioxidants such as anthraquinones, flavonoids, and 3-ol flavan derivatives. *C. fistula* pulp contains several compounds including 1,8-dihydroxy-3-anthraquinone, high concentrations of sucrose, fructose, and glucose, and a good source of macromineral elements such as calcium and potassium [16, 17]. The aqueous extract has shown antioxidant activity in DPPH (2,2-diphenyl-1-picrylhydrazyl), NO (Nitric oxide), and hydroxide radical test [16]. Flavonoids can inhibit many enzymes involved in the oxidation process [17]. A study by Antinosamy *et al* showed that *C. fistula*-derived rhein could reduce MPO activity levels, but the present study denies the role of *C. fistula* aqueous extract in reducing MPO. Increasing the amount of rhein in the extract can be seen in this effect. Tamaki Yamada examined how acetic acid-induced colitis in rats and concluded that the inflammation and tissue damage seen in IBD in humans may be the result of pathological immunological activation (autoimmunity, infectious agent, etc.), while inflammation caused by acetic acid or ethanol causes extensive mucosal damage [18]. The results of the present study also show that induction of colitis in rats increased colon weight and increased inflammation in all animals. *C. fistula* extract concentrations significantly reduced the area involved in the colon

compared to the normal saline group ($P < 0.05$). Bhakta *et al.* studied the anti-inflammatory effects of *C. fistula*, as compared with phenylbutazone, using carrageenan, histamine, and dextran-induced paw edema in rats, and anti-inflammatory activity against all phlogistic agents was noticed [36]. Another study was performed to evaluate the anti-inflammatory effect of ethanolic extract *C. fistula* of leaf and results showed that cassia-pulp extract significantly inhibited both the carrageenan-induced hind paw edema and cotton-pellet granuloma in a dose-dependent manner. Another study has reported the anti-inflammatory activity of aqueous and alcoholic extracts of *C. fistula* bark in sub-acute models of inflammation. results confirmed that extracts showed significant antiinflammatory effects in both air pouch granuloma and cotton pellet granuloma models(new). Studies have shown that *C. fistula* can also be effective in wound healing. The study of Kumar *et al.* Showed that the ointment prepared from *C. fistula* extract can help the wound to heal with its antimicrobial effect against pathogens in the wound as well as increasing the activity of fibroblasts [19]. The etiology of IBD is unclear, but two theories are more common: the dysregulation of the immune system (due to genetic or environmental factors), abnormal factors in the gastrointestinal tract such as microorganisms that make up the intestinal flora, oxidative stress, and defects in the gastrointestinal tract. Which increases its permeability to luminal factors. *C. fistula* has been reported in Iranian medicine sources as an effective plant in IBD. One of the effective methods of this plant can be its significant antimicrobial effects. According to the results of this study and the anti-inflammatory effect of *C. fistula* in the acetic acid model, another *C. fistula* mechanism could have anti-inflammatory effects [20].

CONCLUSION

In Conclusion, the findings of this study showed that *C. fistula* plant extract has positive effects on the healing process of ulcerative colitis, reduction of inflammation, and colitis symptoms. The composition of the aqueous extract of *C. fistula* plant is effective in reducing the activity of the MPO enzyme in comparison with the control group. Due to the composition of *C. fistula* plant, it can be used as an adjunct in the healing process of colitis.

Declaration

Ethics Approval and Consent to Participate

Before conducting the study, the code of ethics was obtained from the ethics committee of Shahid Sadoughi University of Medical Sciences (ID IR.SSU.MEDICINE.REC.1397.232).

Competing Interests

No conflict of interest

Funding

The paper was extracted from the PharmD thesis. Dissertation of the second author, Department of Pharmacology, School of Pharmacy Shahid Sadoughi University of Medical Sciences and Health Services, Yazd, Iran.

Authors' Contributions

Conceptualization, Supervision, and Methodology: M.Z, R.Z; Investigation: All of the authors; Writing – original draft: A.A; Review & editing: M.Z, R.Z; Data collection: A.A; Data analysis: R.Z; Funding Administration: M.Z.

ACKNOWLEDGMENTS

This work was supported by the School of Pharmacy, Shahid Sadoughi University of Medical Sciences, Yazd, Iran.

REFERENCES

1. Hanauer S.B. Inflammatory bowel disease: epidemiology, pathogenesis, and therapeutic opportunities. *Inflammatory Bowel Diseases*. 2006;12(suppl_1):S3-S9.
2. Wang J., Fu Y.X. Tumor necrosis factor family members and inflammatory bowel disease. *Immunological reviews*. 2005;204(1):144-55.
3. Colitis–Pathophysiology U. Inflammatory bowel disease part I: ulcerative colitis–pathophysiology and conventional and alternative treatment options. *Alternative Medicine Review*. 2003;8(3):247-83.
4. Hawkins H.P. An address on the natural history of ulcerative colitis and its bearing on treatment. *British Med. J*. 1909;1(2517):765.
5. Kathleen A. Head N., Jurenka J.S. Inflammatory bowel disease part I: ulcerative colitis–pathophysiology and conventional and alternative treatment options. *Alternative Medicine Review*. 2003;8(3):247-83.
6. Taherkhani R., Ahmadi B., Farshad Pour F., Esmaeilzadeh M., Dolatshahi M., Makvandi M., *et al.* Epidemiologic Characteristics and Frequency of Anatomical Pattern of Ulcerative Colitis in Patients Referred to Imam Khomeini Hospital During Years 2007 to 2011. *Jundishapur Scientific Med. J*. 2014;13(3):276-81.
7. Bernstein C.N., Wajda A., Svenson L.W., MacKenzie A., Koehoorn M., Jackson M., *et al.* The epidemiology of inflammatory bowel disease in Canada: a population-based

- study. American J. Gastroenterology. 2006;101(7):1559-68.
8. Erik B., Van Wyk M.W. Medicinal plants of the world. Briza Publications. 2009.
 9. Khan W., Subhan S., Shams D.F., Afridi S.G., Ullah R., Shahat A.A., *et al.* Antioxidant Potential, Phytochemicals Composition, and Metal Contents of *Datura alba*. Biomed. Res. Int. 2019;2019:2403718-.
 10. Fabia R., Willen R., Ar'Rajab A., Andersson R., Ahren B., Bengmark S. Acetic acid-induced colitis in the rat: a reproducible experimental model for acute ulcerative colitis. European Surgical Res. 1992;24(4):211-25.
 11. Noronha-Blob L., Lowe V.C., Muhlhauser R.O., Burch R.M.J.G. NPC 15669, an inhibitor of neutrophil recruitment, is efficacious in acetic acid-induced colitis in rats. 1993;104(4):1021-9.
 12. MacPherson B., Pfeiffer C.J.D. Experimental production of diffuse colitis in rats. 1978;17(2):135-50.
 13. Chou T.C. Anti-inflammatory and analgesic effects of paeonol in carrageenan-evoked thermal hyperalgesia. British J. Pharma. 2003;139(6):1146-52.
 14. Kappelman M.D., Moore K.R., Allen J.K., Cook S.F. Recent trends in the prevalence of Crohn's disease and ulcerative colitis in a commercially insured US population. Digestive Diseases and Sci. 2013;58(2):519-25.
 15. Murad H.A., Abdallah H.M., Ali S.S. *Mentha longifolia* protects against acetic-acid induced colitis in rats. J. Ethnopharmacology. 2016;190:354-61.
 16. Ali M.A. *Cassia fistula* Linn: a review of phytochemical and pharmacological studies. Int. J. Pharm. Sci. Res. 2014;5(6):2125-30.
 17. Rahmani A.H. *Cassia fistula* Linn: Potential candidate in the health management. Pharmacognosy Res. 2015;7(3):217.
 18. Yamada T., Marshall S., Specian R.D., Grisham MB. A comparative analysis of two models of colitis in rats. Gastroenterology. 1992;102(5):1524-34.
 19. Kumar M.S., Sripriya R., Raghavan H.V., Sehgal P.K. Wound healing potential of *Cassia fistula* on infected albino rat model. J. Surgical Res. 2006;131(2):283-9.
 20. Rahimi R., Shams-Ardekani M.R., Abdollahi M. A review of the efficacy of traditional Iranian medicine for inflammatory bowel disease. World J. Gastroenterology: WJG. 2010;16(36):4504.